



## Pyomyositis. A literature review

Georgios DROSOS

*From Athens Naval Hospital, Athens, Greece*

**Pyomyositis is a primary bacterial infection of the skeletal muscles. It is known as tropical myositis as most cases have been reported in patients living in tropical areas and, until recently, it was considered unusual in the temperate zone. The condition is usually diagnosed late, and for this reason it is followed by an increased morbidity and sometimes a significant mortality rate. A review of the literature indicates a possibly rising incidence in non-tropical areas. This condition should be considered in patients with muscle pain, fever, leucocytosis, elevated ESR and CRP, in tropical and non-tropical countries, in previously healthy patients as well as in patients suffering other health problems, particularly HIV infection. An MRI investigation should be performed early as it is the imaging technique of choice during the first stage of the disease. A case of a primary iliopsoas pyomyositis diagnosed during the initial stage using MRI is presented as an illustration**

### INTRODUCTION

Pyomyositis is a primary bacterial infection of the skeletal muscles (4, 8, 26, 41, 46). Although it is known as tropical myositis as most cases have been reported in patients living in tropical areas, reports from non-tropical areas have increased (2, 14, 17, 33). The disease is usually diagnosed late and, for this reason, it is followed by an increased morbidity and sometimes a significant mortality rate (1, 8, 26, 27, 33).

Iliopsoas pyomyositis is usually secondary to direct invasion from an adjacent source of infection such as spinal, gastrointestinal or urinary tract infection (8, 9, 13, 19, 22, 30, 38, 51, 55). Primary iliopsoas pyomyositis is rare and is usually diagnosed late during the purulent stage (33-35, 55).

A case of primary iliopsoas pyomyositis diagnosed during the initial stage using MRI is presented. A review of the literature indicates a possibly rising incidence of pyomyositis in non-tropical areas and a changing presentation as the disease is more often diagnosed in patients having general health problems, particularly HIV infection.

### CASE REPORT

A 42-year-old female patient presented with a three-day history of left hip pain and limping. There was no history of trauma or correlated past illness. The patient was not on any medication and she had not traveled abroad for a long time.

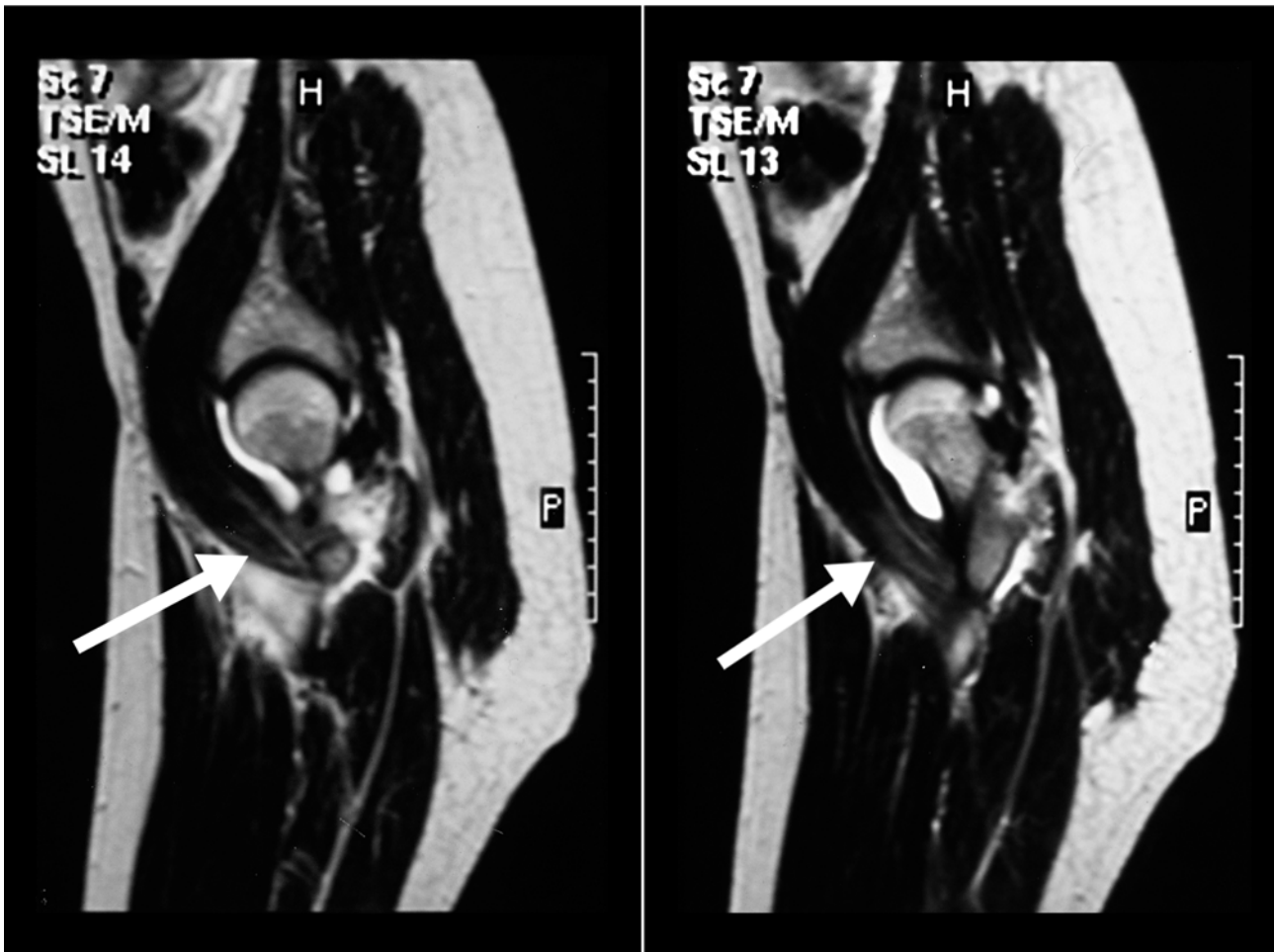
---

■ Georgios Drosos, MD, PhD, Orthopaedic Surgeon.  
Second Orthopaedic Department, Athens Naval Hospital,  
Deinokratous 70, 11521 Athens, Greece.

Correspondence : Georgios I. Drosos, Ag. Sofias 29, 15451  
N. Psihiko, Athens, Greece. E-mail : drosos@otenet.gr.

© 2005, Acta Orthopædica Belgica.

---



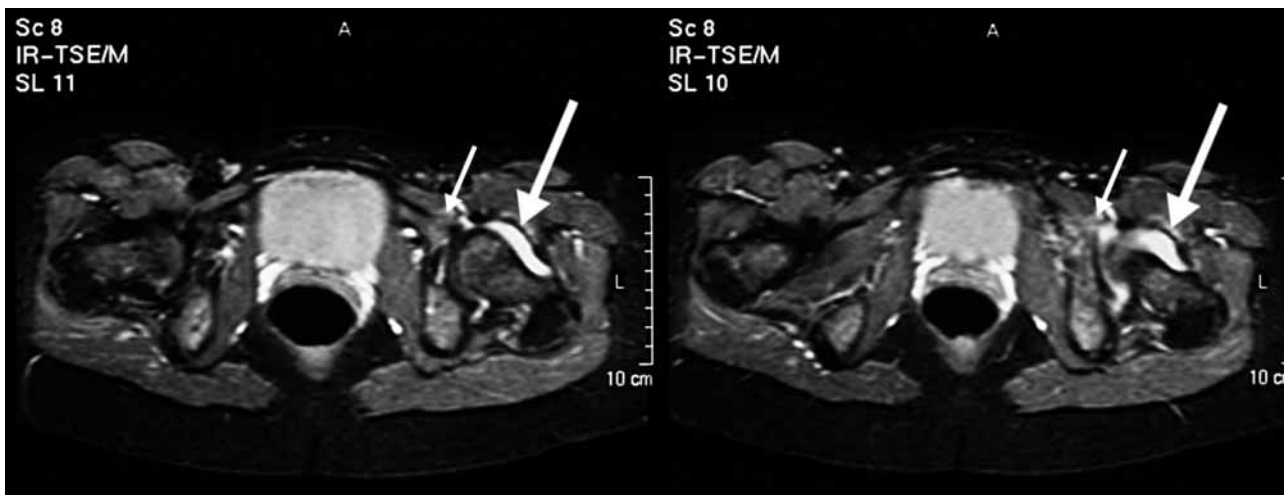
*Fig. 1.* — Frontal view of the left hip showing an increased signal on T2-weighted images involving the iliopsoas muscle, and fluid collection in the hip joint.

Clinically, she was limping, the movements of the hip were restricted and painful, and her temperature was 37.8°C. Radiographs were normal, full blood count showed leucocytosis of  $12 \times 10^3/\text{mm}^3$  with increased neutrophils, erythrocyte sedimentation rate (ESR) of 30 mm in 1 hour and C-reactive protein (CRP) was 38 mg/l.

An urgent MRI examination of the pelvis and hips showed an increased signal on T2-weighted images involving the left iliopsoas muscle as well as fluid collection inside the hip joint (fig 1, 2). A CT-guided hip aspiration was performed. No microorganisms were identified on Gram stain, but the fluid was inflammatory with neutrophiles.

In 48 hours the clinical picture became more severe than it was on admission, the ESR raised to 89 mm/hr and CRP was 96.8 mg/l, but no microorganisms were cultured in the joint fluid. The provisional diagnosis was infectious myositis of the iliopsoas muscle and intravenous antibiotic treatment with Ciprofloxacin and Rifabycin was started.

The pain significantly subsided. There was an obvious improvement in the movements of the hip in 24 hours. ESR and CRP values dropped. In one week the patient was able to walk without support, and ESR and CRP were back to normal values in ten days.



**Fig. 2.** — T2-weighted images of the pelvis showing an increased signal involving the left iliopsoas muscle (small arrow) and fluid collection inside the hip joint (large arrow).

Despite an extensive clinical and laboratory investigation including ultrasound and CT-scan examination of the abdomen, pelvis and lumbar spine, and laboratory tests for rheumatologic, autoimmune, connective tissue and immunodeficiency disorders, including HIV infection, no other abnormality was found. Cultures of the joint fluid for tuberculosis were also negative.

The antibiotic treatment was continued intravenously for 2 weeks and orally for another 4 weeks. Two weeks later, a new MRI showed improvement of the increased signal on T2-weighted images of the left iliopsoas muscle and the patient was discharged from the hospital; she was asymptomatic.

Clinical and laboratory checks 6 weeks, 3 months and 6 months later revealed no signs of infection. A further MRI at six months was normal and the patient has remained asymptomatic for almost one year now.

## DISCUSSION

### History

Traquair (46) credited Virchow for the earliest mention of pyomyositis but according to Patel *et al* (33), the first true description was probably by

Scriba in 1885, as a disease endemic to the tropics - hence the term, tropical pyomyositis. Until recently, pyomyositis was indeed considered as unusual in the temperate zone (39).

Later on, it was noted that the number of reported cases of pyomyositis in temperate climates had increased (2, 14, 17, 33). Over the last decades there has been growing concern as the disease has been reported with increasing frequency in the United States (44) and North America (10, 18) as well as in other non-tropical areas like European countries (16, 20, 29).

Most reports have been case reports or reports of small series of patients (5) and thus the true prevalence of pyomyositis in non-tropical areas has not as yet been actually determined. It is not clear whether its incidence in non-tropical areas has really increased, or whether the disease is more recognised (8).

Nevertheless we should probably adopt the statement that “pyomyositis is a disease of both temperate and tropical climates” (33).

### Demographics

The tropical disease occurs in all age groups with a peak incidence at two age ranges, from two to five and from 35 to 40 years, with a male to

female ratio of 4:1 (8). The non-tropical disease shows a 30-50 and 60-70 years peak, with a 3:1 male to female ratio (15). In a recent review of 676 reported cases, the ages of the patients ranged from two months to 82 years, it was more common in the first and second decades of life and there was a slight male predominance (5).

### Involvement

Although any skeletal muscle can be involved, the disease has a predilection for the large muscle masses of the body (8, 33). The most common site of involvement is the quadriceps muscle (65%), followed by the gluteal muscles (35%) (8).

Multiple muscle involvement occurs in 12-60% of the patients (5, 8, 17, 26, 41, 46).

No significant difference between tropical and non-tropical cases was found regarding the topographical involvement (15).

### Pathology-presentation

Pyomyositis usually presents as a subacute infection of skeletal muscle, but may also present as a diffuse inflammatory or a rapidly progressing myonecrotic process (36, 41, 43, 48).

The presentation of the disease depends on its stage when the patient is first seen. Typical pyomyositis has been divided in three clinical stages (8). Only 2% of the patients presented at the first stage, the so-called "invasive stage" lasting about ten days. Signs of inflammation are minimal. The patients present with muscle pain, fever, mild leukocytosis, and elevated ESR. Other findings may be anaemia and eosinophilia (in tropical cases) (8). The second stage is the "suppurative stage". Usually this stage is between 10 and 21 days from the onset of symptoms. More than 90% of the patients presented in this stage. Signs of inflammation are more marked with tenderness and marked oedema of the muscle, fever and leukocytosis (8). The final stage is the "late stage". The patient is truly sick, with high fever, toxicity and occasionally septicaemia and coma may be found. About 5% of the patients presented in this stage (8).

Although classically healthy young males develop the disease, atypical presentation may occur in patients with comorbid conditions such as human immunodeficiency virus (HIV) infection, diabetes mellitus, haemopoietic disorders, and other conditions with defective neutrophil function (5, 33).

### Aetiology-pathogenesis

Tropical pyomyositis was described in association with tropical climate and occasionally in association with trauma, parasites, nutritional deficiencies, viruses and spirochetes and it was therefore suggested that these are possibly aetiological factors (8, 39), but data from a recent review do not support this suggestion (5).

Non-tropical pyomyositis has been recognised with increasing frequency in individuals with HIV infection (5, 9, 14, 17, 18, 33, 49, 50) and other chronic conditions such as diabetes mellitus, dermatomyositis or malignant disease (14, 17, 18, 33, 39).

In a review of English-language literature, Gomez-Reino *et al* (15) found that about two-thirds of the patients with non-tropical pyomyositis have been reported to have comorbid conditions such as HIV infection, diabetes mellitus, haemopoietic disorders, and other conditions with defective neutrophil function.

Bickels *et al* (5) in a review study of all reported cases found that approximately half of the patients presenting with pyomyositis when they are more than thirty years of age have an underlying condition.

### Micro-organisms

Staphylococcus is the most common organism, accounting for 90% of the cases (8). In non-tropical cases the frequency of staphylococcal infection is lower -about 60% - while other microorganisms are involved in about 40% of the cases (15).

### Investigation

Routine laboratory tests show leukocytosis with elevated neutrophil count, an elevated ESR,

normal creatine phosphokinase and aldolase, and in tropical cases eosinophilia has also been reported (8, 9, 15, 28, 33).

Blood cultures were positive only in 5% of tropical cases (8) whereas in non-tropical cases septicaemia was more frequently reported, in about one-third of the patients (31, 33).

Plain radiography is used essentially to rule out bony lesions, as radiological findings suggestive of muscle infection are rare (2, 42).

MRI shows (a) a diffuse muscle enlargement and an increased signal intensity on T2-weighted image during the initial stage and (b) the muscle abscess with a high-signal-intensity rim on T1-weighted image during the later stage (3, 12, 54). Thus MRI aids in early diagnosis, staging of the disease and differential diagnosis (3, 12, 23, 32, 37, 54).

CT demonstrates an asymmetric muscle enlargement, focal areas of low attenuation or gas formation and a peripheral enhancement after contrast medium injection (17, 28, 33, 48, 55).

Ultrasonography also shows an abnormal echotexture of a bulky muscle with a hypo-echoic focal lesion occasionally containing internal debris and air bubbles (28, 45, 50).

CT and ultrasonographic features may not be specific during the early "invasive" phase of the disease as they may fail to demonstrate the diffuse inflammatory changes, but both are useful in guiding percutaneous catheter drainage of the abscess during later stages (30, 44, 53, 54).

### Diagnosis and differential diagnosis

Diagnosis is often delayed because (a) the patients usually present late, (b) the disease is rare and physicians are not familiar with the entity, (c) the symptoms and clinical signs during the initial stage are atypical and (d) many patients have an underlying condition (5, 8, 33).

Differential diagnosis depends on the area involved and includes osteomyelitis, deep venous thrombosis, cellulitis, haematoma, malignant tumours, synovitis, septic arthritis, and, for iliopsoas pyomyositis, appendicitis, diverticulitis and other causes of peritonitis (17, 21, 33, 39, 51).

### Treatment

Early recognition during the pre-suppurative phase followed by prompt antibiotic treatment will abort the invasion and results, almost always, in rapid resolution of the muscle infection without surgical drainage (8, 11, 34, 44).

The later stages require either incision and drainage (8, 17, 18, 28) or percutaneous catheter drainage under CT or ultrasonographic guidance (30, 44, 55) as well as antibiotic therapy.

### Results

The overall results are very satisfying if the disease is recognised and managed aggressively in the early stages (8, 18, 27).

The late stages carry a penalty of increased morbidity and protracted hospital stay, and may (a) result in local extension to adjacent bone or joint, (b) cause a compartment syndrome, (c) cause a remote infection such as pericarditis, endocarditis, myocarditis, lung and brain abscesses, renal failure, (d) result in septicaemia and (e) cause death (1, 8, 26, 27, 33). Mortality in large reported series varies between 0.89% and 10% (1, 8, 26, 27, 33).

### Iliopsoas pyomyositis

Iliopsoas infection is either primary or - most commonly - secondary to direct invasion from an adjacent source of infection in gastrointestinal, urinary tract or adjacent bony structures (6, 8, 9, 13, 19, 22, 25, 28, 30, 38, 51, 55).

Peripelvic deep soft tissue, muscular, and joint infection can pose a diagnostic challenge for the emergency physician (24, 40, 51) and some authors believe that MRI of the pelvis should be undertaken at an early stage (32, 47).

Pyomyositis of the iliopsoas is typically associated with fever, hip pain and limping and the affected hip is held in flexion and external rotation (2, 7, 28, 35). Hip movements are painfully restricted and internal rotation and extension in particular, usually elicit pain by stretching the iliopsoas muscle (2, 7, 35).

Very often other symptoms such as back pain, femoral neuropathy or lower abdominal pain are present and thus the clinical presentation of primary iliopsoas pyomyositis is often insidious, symptoms and signs are often obscure and diagnosis and treatment are therefore often delayed (33-35, 55). Thus most of the cases have been diagnosed during the second or third stage when an iliopsoas abscess has been formed ; even then, the diagnosis is often not considered at first and many cases have been treated for various other conditions (20, 21, 28, 33, 51, 55).

Differential diagnosis of iliopsoas pyomyositis should include septic arthritis, osteomyelitis, thrombophlebitis, cellulitis, haematoma, malignant tumours, appendicitis, diverticulitis and other causes of peritonitis (20, 21, 33, 51, 55).

Clinically, the most common and recognised disease associated with limping, hip pain and fever is septic hip arthritis and it is difficult to differentiate septic arthritis from pyomyositis (2, 7, 9, 21).

Treatment of primary iliopsoas pyomyositis is the same as in other myositis. Most of the cases have been treated with drainage and antibiotics as they have been diagnosed late and very few cases have been treated with antibiotics alone (6, 8, 28, 33, 55).

In our case the clinical and laboratory findings of infection, the MRI findings of muscle oedema, and the improvement after antibiotic treatment were consistent with muscle infection. We suggest that the hip joint fluid was reactive as no microorganisms were isolated.

Differential diagnosis of muscle oedema includes trauma, overuse, intramuscular haemorrhage, other types of myositis, early stage of denervation, collagen vascular disease, radiation, necrosis, tumour, venous thrombosis (51, 52).

The extensive clinical and laboratory investigation as well as the clinical course with the antibiotic treatment have excluded other diagnoses in our patient. Should there have existed a history of trauma or overuse, this could not have excluded pyomyositis. Most of the other causes should have a history or specific clinical and/or laboratory findings. In any case initiation of antibiotic treatment for pyomyositis does not impose any additional dif-

ficulty in diagnosing these conditions while early treatment of pyomyositis markedly improves the outcome. In our case MRI was valuable in diagnosing the lesion early as well as in demonstrating the improvement after two weeks of treatment.

## CONCLUSION

Although pyomyositis is not common, it should be considered in patients with muscle pain, fever, leucocytosis, elevated ESR and CRP, in tropical and non-tropical countries, in previously healthy patients as well as in those having co-morbid conditions.

An MRI investigation should be performed early as it is the imaging study of choice during the first stage of the disease.

Based on the existing literature, one could suggest that any patient with signs of infection with muscle pain, fever, leucocytosis, elevated ESR and CRP, and muscle oedema on MRI in a single muscle, should be treated early with antibiotics as a pyomyositis in order to avoid the increased morbidity and significant mortality that characterise the disease when is diagnosed during later stages. In the same time other sites of infection and other causes of muscle oedema should be excluded.

## REFERENCES

1. **Anand SV, Evans KT.** Pyomyositis. *Br J Surg* 1964 ; 51 : 917-920.
2. **Andrew JG, Czyz WM.** Pyomyositis presenting as septic arthritis : a report of two cases. *Acta Orthop Scand* 1988 ; 59 : 587-588.
3. **Applegate GR, Cohen AJ.** Pyomyositis : early detection utilizing multiple imaging modalities. *Magn Reson Imaging* 1991 ; 9 : 187-193.
4. **Ashken MH, Cotton RE.** Tropical skeletal muscle abscesses (Pyomyositis tropicans). *Br J Surg* 1963 ; 50 : 846-852.
5. **Bickels J, Ben-Sira L, Kessler A, Wientroub S.** Primary pyomyositis. *J Bone Joint Surg* 2002 ; 84-A : 2277-2286.
6. **Cantademir M, Kara B, Cebi D et al.** Computed tomography-guided percutaneous catheter drainage of primary and secondary iliopsoas abscesses. *Clin Radiol* 2003 ; 58 : 811-815.
7. **Chen W-S, Wan YL.** Iliacus pyomyositis mimicking septic arthritis of the hip joint. *Arch Orthop Trauma Surg* 1996 ; 115 : 233-235.

8. Chiedozi LC. Pyomyositis. Review of 205 cases in 112 patients. *Am J Surg* 1979 ; 137 : 255-259.
9. Christin L, Sarosi GA. Pyomyositis in North America : case reports and review. *Clin Infect Dis* 1992 ; 15 : 668-677.
10. Dunkerley GR, Older J, Onwochei B, Paziienza J. Pyomyositis. *Am Fam Physician* 1996 ; 54 : 565-569.
11. Fam G, Rubenstein J, Saibh F. Pyomyositis : Early detection and treatment. *J Rheumatol* 1993 ; 20 : 521-524.
12. Fleckenstein JL, Burns DK, Murphy PK *et al.* Differential diagnosis of bacterial myositis in AIDS : evaluation with MR imaging. *Radiology* 1991 ; 170 : 653-658.
13. Franco-Paredes C, Blumberg HM. Psoas muscle abscess caused by Mycobacterium tuberculosis and Staphylococcus aureus : case report and review. *Am J Med Sci* 2001 ; 321 : 415-417.
14. Gibson RK, Rosenthal SJ, Lufert BP. Pyomyositis increasing recognition in temperate climates. *Am J Med* 1984 ; 77 : 768-772.
15. Gomez-Reino JJ, Aznar JJ, Pablos JL *et al.* Nontropical pyomyositis in adults. *Semin Arthritis Rheum* 1994 ; 23 : 396-405.
16. Gyssens IC, Timmermans UM. Tropical pyomyositis. *Neth J Med* 1989 ; 34 : 205-209.
17. Hall RL, Callaghan JJ, Moloney E *et al.* Pyomyositis in a temperate climate. *J Bone Joint Surg* 1990 ; 72-A : 1240-1244.
18. Hossain A, Reis ED, Soundararajan K *et al.* Nontropical pyomyositis : analysis of eight patients in an urban center. *Am Surg* 2000 ; 66 : 1064-1066.
19. Huang JJ, Ruaan MK, Lan RR, Wang MC. Acute pyogenic iliopsoas abscess in Taiwan : clinical features, diagnosis, treatments and outcome. *J Infect* 2000 ; 40 : 248-255.
20. Iwuagwu OC, Deans GT. Pyomyositis mimicking right iliac fossa mass : review of the literature. *Ann R Coll Surg Engl* 2000 ; 82 : 352-354.
21. Jou I-M, Chiu N-T, Lai K-A, Chuang Y-C. Synchronous pyomyositis and septic hip arthritis. *Clin Radiol* 2000 ; 19 : 385-388.
22. Kao PF, Tsui KH, Leu HS *et al.* Diagnosis and treatment of pyogenic psoas abscess in diabetic patients : usefulness of computed tomography and gallium-67 scanning. *Urology* 2001 ; 57 : 246-251.
23. Kim JY, Park YH, Choi KH *et al.* MRI of tuberculous pyomyositis. *J Comput Assist Tomogr* 1999 ; 23 : 454-457.
24. King RJ, Laugharne D, Kerslake RW, Holdsworth BJ. Primary obturator pyomyositis : a diagnostic challenge. *J Bone Joint Surg* 2003 ; 85-B : 895-898.
25. Lam SF, Hodgson AR. Non-spinal pyogenic psoas abscess. *J Bone Joint Surg* 1966 ; 48-A : 867-877.
26. Levin MJ, Gardner P, Waldvogel FA. An unusual infection due to staphylococcus aureus. *N Engl J Med* 1971 ; 284 : 196-198.
27. Malhotra P, Singh S, Sud A, Kumari S. Tropical pyomyositis : experience of a tertiary care hospital in north-west India. *J Assoc Physicians India* 2000 ; 48 : 1057-1059.
28. Malhotra R, Singh KD, Bhan S, Dave PK. Primary pyogenic abscess of the psoas muscle. *J Bone Joint Surg Am* 1992 ; 74 : 278-284.
29. Meletis J, Yataganas X, Vayopoulos G *et al.* Tropical pyomyositis in a Greek adult. *Scand J Infect Dis* 1989 ; 21 : 343-344.
30. Mueller PR, Ferrucci JT Jr, Wittenberg J *et al.* Iliopsoas abscess : treatment by CT-guided percutaneous catheter drainage. *AJR Am J Roentgenol* 1984 ; 142 : 359-362.
31. Muscat I, Anthony PP, Cruickshank JG. Non tropical pyomyositis. *J Clin Pathol* 1986 ; 39 : 1116-1118.
32. Papadopoulos M, Chugh S, Fitzgerald R, Thomas RJ. Obturator internus pyomyositis. *Orthopedics* 2000 ; 23 : 383-384.
33. Patel SR, Oleginski TP, Perruquet JL, Harrington TM. Pyomyositis : clinical features and predisposing conditions. *J Rheumatol* 1997 ; 24 : 1734-1738.
34. Peckett WR, Butler-Manuel A, Apthorp LA. Pyomyositis of the iliacus muscle in a child. *J Bone Joint Surg* 2001 ; 83-B : 103-105.
35. Perry J, Barrack RL, Burke SW, Haddad RJ Jr. Psoas abscess mimicking a septic hip. Diagnosis by computed tomography. *J Bone Joint Surg* 1985 ; 67-A : 1281-1283.
36. Raphael SA, Wolfson BJ, Parker P *et al.* Pyomyositis in a child with acquired immunodeficiency syndrome. Patient report and brief review. *Am J Dis Child* 1989 ; 143 : 779-781.
37. Renwick SE, Ritterbusch JF. Pyomyositis in children. *J Pediatr Orthop* 1993 ; 13 : 769-772.
38. Ricci MA, Rose FB, Meyer KK. Pyogenic psoas abscess : worldwide variation in etiology. *World J Surg* 1986 ; 10 : 834-843.
39. Schleich III WF, Mouhon P, Kaiser AB. Pyomyositis : tropical disease in a temperate climate. *Am J Med* 1981 ; 71 : 900-902.
40. Sharieff GQ, Lee DM, Anshus JS. A rare case of salmonella-mediated sacroiliitis, adjacent subperiosteal abscess, and myositis. *Pediatric Emergency Care* 2003 ; 19 : 252-254.
41. Shepherd JJ. Tropical myositis : is it an entity and what is its cause ? *Lancet* 1983 ; 2 : 1240-1242.
42. Simons GW, Sty JR, Starshak RR. Iliacus abscess. *Clin Orthop* 1984 ; 183 : 61-63.
43. Sirinavin S, McCracken GH Jr. Primary suppurative myositis in children. *Am J Dis Child* 1979 ; 133 : 263-265.
44. Spiegel DA, Meyer JS, Dormans JP *et al.* Pyomyositis in children and adolescents : report of 12 cases and review of the literature. *J Pediatr Orthop* 1999 ; 19 : 143-150.
45. Tong CW, Griffith JF, Lam TP, Cheng JC. The conservative management of acute pyogenic iliopsoas abscess in children. *J Bone Joint Surg* 1998 ; 80-B : 83-85.

46. **Traquair RN.** Pyomyositis. *J Trop Med Hyg* 1947 ; 50 : 81-89.
47. **Tsirantonaki M, Michael P, Koufos C.** Pyomyositis. *Clin Rheumatol* 1998 ; 17 : 333-334.
48. **Tumeh SS, Butler GJ, Maguire JH, Nagel JS.** Pyogenic myositis : CT evaluation. *J Comput Assist Tomogr* 1988 ; 12 : 1002-1005.
49. **Watts RA, Hoffbrand BI, Paton DF, Davis JC.** Pyomyositis associated with human immunodeficiency virus infection. *Br J Med (Clin Res Ed)* 1987 ; 294 : 1524-1525.
50. **Widrow CA, Kellie SM, Saltzman BR et al.** Pyomyositis in patients with the human immunodeficiency virus. An unusual form of disseminated bacterial infection. *Am J Med* 1991 ; 91 : 129-136.
51. **Wysoki MG, Angeid-Backman E, Izes BA.** Iliopsoas myositis mimicking appendicitis : MRI diagnosis. *Skeletal Radiol* 1997 ; 26 : 316-318.
52. **Vehleisiek M, Layer G.** Musculature. In : Vehleisiek M, Genant HK, Reiser M (eds). *MRI of musculoskeletal system*. Thieme, Stuttgart-New York 2000 : pp 257-282.
53. **Youseladeh DK, Schumann EM, Muligan GM et al.** The role of imaging modalities in diagnosis and management of pyomyositis. *Skeletal Radiol* 1982 ; 9 : 285-289.
54. **Yuh WT, Schreiber AE, Montgomery WJ, Ehara S.** Magnetic resonance imaging of pyomyositis. *Skeletal Radiol* 1988 ; 17 : 190-193.
55. **Zissin R, Gayer G, Kots G et al.** Iliopsoas abscess : a report of 24 patients diagnosed by CT. *Abdom Imaging* 2001 ; 26 : 533-539.