



## Traumatic anterior dislocation of the hip joint with posterior acetabular wall fracture

Manish CHADHA, Anil AGARWAL, Arun Pal SINGH

From the Department of Orthopaedics, UCMS and GTB Hospital, Delhi, India

The incidence of traumatic hip dislocation has increased in recent years as a result of high-energy trauma. Anterior hip dislocation forms less than 10-15% of all traumatic hip dislocations. Only a few case reports describe anterior dislocation along with acetabular fractures. The acetabular fracture involved the anterior wall or column in all such cases. We describe a rare case in which anterior superior dislocation of the hip was associated with a large fracture fragment of the posterior acetabular rim and adjacent wall.

### INTRODUCTION

Anterior hip dislocation forms less than 10-15% of all traumatic hip dislocations and compared to the more common posterior variety, its ratio is 1:20 to 1:10 in large series (3). Anterior dislocations of the hip are classified as obturator, pubic or perineal types (2). The pubic superior anterior hip dislocation accounts for less than 10% of anterior hip dislocations in most series (5). Only a few case reports describe anterior dislocation along with acetabular fractures; the latter usually affect the anterosuperior part of the acetabulum, the anterior inferior iliac spine and/or the anterior superior iliac spine (6, 7, 10). This report describes a rare case in which anterior superior dislocation of hip was associated with a large fracture fragment of the posterior acetabular rim and adjacent wall.

### CASE REPORT

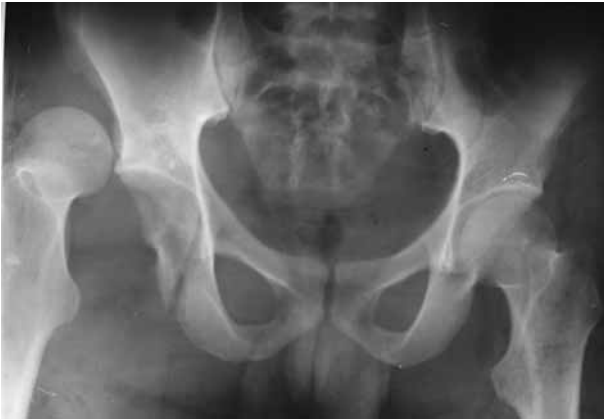A 24-year-old male sustained injury when he fell off his motorcycle. On examination, the right lower limb was grossly shortened and fixed in external rotation and abduction. There was swelling in the right hip region and upper thigh along with swelling and tenderness in the right leg with abnormal mobility and crepitus. The patient was haemodynamically stable with no neurovascular deficit. Radiographs revealed a superior variety of anterior dislocation of the right hip with a fracture of the posterior acetabular wall (fig 1) and an ipsilateral midshaft fracture of the tibia and fibula. Computerized tomography of the right hip showed an anteriorly dislocated femoral head lying externally rotated and in relation to the superolateral aspect of the ilium. A large displaced fracture of the posterior acetabular rim and wall with several loose fragments within the acetabulum was seen (fig 2a, b). An upper tibial Steinman pin was applied and incorporated into a below knee cast to splint the fractured leg bones. Under anaesthesia, a closed

- 
- Manish Chadha M.S. (Ortho.), Senior Lecturer.
  - Anil Agarwal M.S. (Ortho.), Senior Resident.
  - Arun Pal Singh M.S. (Ortho.), Senior Resident.

Correspondence : Manish Chadha, C-A/16, Tagore Garden, New Delhi-110027, India. E-mail : [mchadha@hotmail.com](mailto:mchadha@hotmail.com), [drmanishchadha@yahoo.com](mailto:drmanishchadha@yahoo.com).

© 2004, Acta Orthopædica Belgica.

---

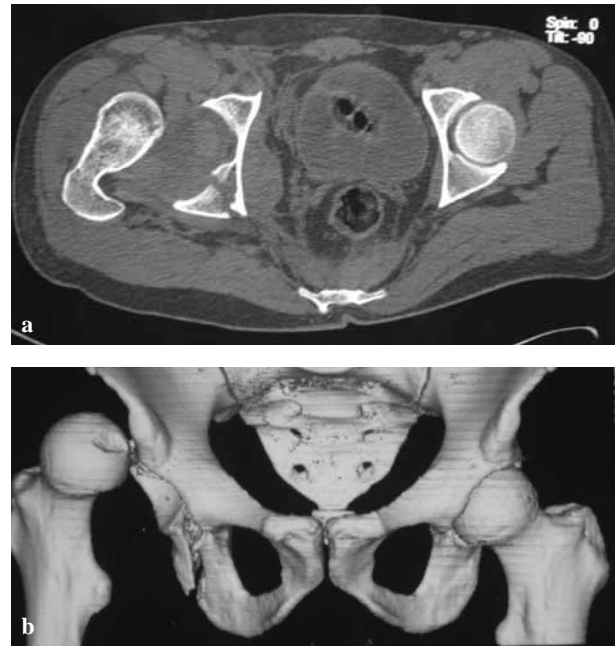


**Fig. 1.** — Radiographs of pelvis at presentation, showing anterior dislocation of the right hip with a fracture of the posterior acetabular wall. Note the prominent lesser trochanter which suggests external rotation of the hip – a classical radiological feature of anterior dislocation.

reduction of the dislocated hip was performed using strong longitudinal traction through the tibial pin, direct force on the femoral head and gradual flexion and internal rotation. Once closed reduction of the dislocation was achieved, the acetabular fracture was exposed using a posterolateral approach and was stabilised with a reconstruction plate (fig 3). The tibial fracture was also fixed at the same time. Postoperatively, the patient was allowed 'on-traction' mobilisation exercises of the hip in bed. At 6 weeks, he was allowed non-weight bearing ambulation with crutches. By 12 weeks, union was present at the fractures of the tibia and fibula, and the right hip was pain free, showing full range of movements.

## DISCUSSION

Traumatic dislocation of the hip in an adult is considered to be the result of very high-energy trauma (1). The dislocation occurs when forces transmitted along the femur force the head of the femur out [dash board injuries] (5). If the thigh was in a position of abduction and external rotation, the resulting dislocation may be anterior. A motorcycle accident is a characteristic example where the limb is kept in abduction and external rotation. Flexion at the hip joint will result in an obturator or perineal

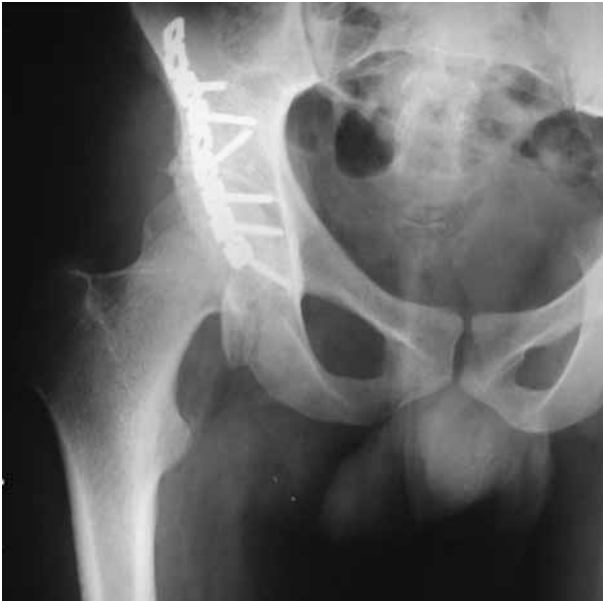

**Fig. 2.** — **a.** Computerised tomograph (transverse section). Anterior dislocation of the femoral head with posterior acetabular wall fracture. The trochanter lies in close relation to the fracture fragment, with a loose fragment within the acetabular cavity; **b.** Computerised tomograph (reconstructed view). Anterior dislocation head of femur lying externally rotated and in relation to the superolateral aspect of the ilium.

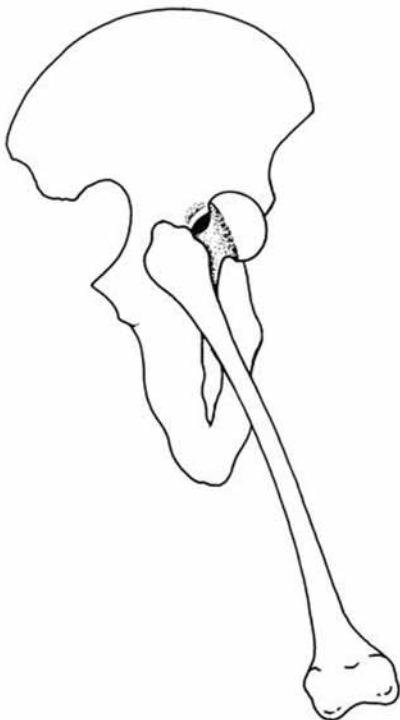
variety of anterior dislocation, while an extended position will result in a pubic type (4). However, the circumstances and exact position of the limb at the time of accident are difficult to determine, and practically impossible in a living subject.

Associated injuries are common and the patient may have a polytrauma presentation (1). The more obvious limb fractures may mask the hip injury. The ipsilateral fracture of the tibia and fibula in our case produced both shortening and an external rotation attitude of the right lower limb. The importance of detailed clinical evaluation of the patient especially in high-energy trauma needs to be emphasised.

Reduction of the pubic dislocation of the femoral head is best performed under general anaesthesia with the patient supine. As described by Epstein (5), a sustained strong traction in line with the femur is necessary to pull the femoral head distal to the acetabulum. The hip is then slowly



**Fig. 3.** — Radiograph after closed reduction of the hip dislocation and surgical stabilisation of the acetabular fragment with a reconstruction plate.



**Fig. 4.** — Illustration showing a possible mechanism. Trochanteric impingement against the posterior acetabular wall produced by abduction and external rotation of the hip joint may lead to fracture of the posterior acetabular wall.

flexed and internally rotated. No adduction should be attempted until the hip is reduced.

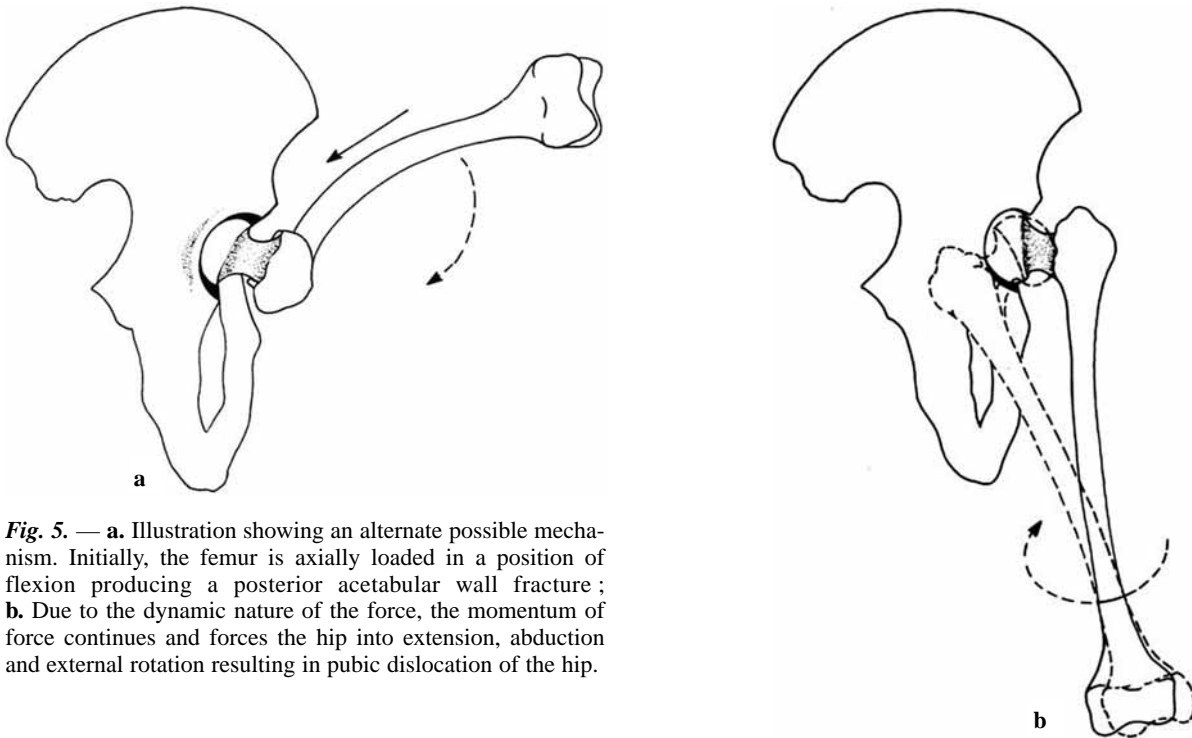
Dingley and Denham (2) suggested that pubic anterior dislocation of the hip is a hyperextension injury. Flexion of the hip is quite impossible in these cases because it serves to tighten the already tight posterior capsular structures. They believe that to reduce such dislocations, the hip should initially be brought into hyperextension. Rotational movements and constant traction along with direct pressure over the femoral head should follow this, accomplishing reduction.

In rare cases, the anterior dislocations require open reduction. The pathological findings described in such cases include femoral head trapped between the medial border of the iliofemoral ligament and the pubocapsular ligaments (7), trapping of the femoral head by the iliopsoas (10) and buttonhole defects with tightening of the capsule about the base of the head (9).

The associated acetabular fracture is very rare. Epstein and Harvey (4) in their large series of 55 anteriorly dislocated hips, mention fracture of the acetabulum in only 2 cases associated with anterior dislocation of the hip. The details of these fractures are not described. Mirovsky *et al* (7) describe a fracture involving anterior and superior parts of acetabulum and the anterior inferior iliac spine along with anterior dislocation of hip. In our case, both the radiographs and the computerised tomography (fig 2a, b) revealed a displaced fracture of the posterior acetabular lip and adjacent wall. No previous observer has mentioned this injury pattern of acetabular fracture along with anterior dislocation of hip.

The mechanisms which resulted in anterior dislocation with fracture of the posterior wall of the acetabulum in the author's opinion could be explained in the following ways :

1. Firstly, as asserted by Epstein (3), the most important factor producing anterior hip dislocation is forcible abduction. The trochanter while abducting impinges upon the acetabulum rim, levering the femur head through the anterior capsule. We believe that this trochanteric impingement against the posterior acetabular



**Fig. 5.** — **a.** Illustration showing an alternate possible mechanism. Initially, the femur is axially loaded in a position of flexion producing a posterior acetabular wall fracture; **b.** Due to the dynamic nature of the force, the momentum of force continues and forces the hip into extension, abduction and external rotation resulting in pubic dislocation of the hip.

wall as produced by gross abduction and external rotation of the hip joint may lead to its fracture. The presence of loose fragments within the acetabulum and the trochanter lying next to the fracture fragment suggest that this may be the probable mechanism (fig 4).

2. Alternatively, the force that would be expected to produce a posterior acetabular fracture is one of axial loading of the femur in a position of flexion, while the force that would result in an anterior dislocation of the hip (superior variety) is one of extension, abduction and external rotation. A possible mechanism to explain this is one of a dynamic force. Initially, the femur was axially loaded in flexion, which produced the posterior acetabular wall fracture. After the fall, the momentum of the force continued and forced the hip into extension, abduction and external rotation, resulting in an anterior dislocation of the hip (superior variety) (fig 5a, b).

This case aims to stress the importance of a complete clinical evaluation in polytrauma patients and attempts to explain the mechanism of injury in this particular fracture combination.

## REFERENCES

1. **Alonso JE, Volgas DA, Giordano V, Stannard JP.** A review of the treatment of hip dislocations associated with acetabular fractures. *Clin Orthop* 2000; 377: 32-43.
2. **Dingley AF, Denham RH.** Pubic dislocation of the hip. *J Bone Joint Surg* 1964; 46-A: 865-867.
3. **Epstein HC.** Traumatic dislocations of the hip. *Clin Orthop* 1973; 92: 116-142.
4. **Epstein HC, Harvey JP, Jr.** Traumatic anterior dislocation of the hip, management and results – An analysis of fifty-five cases. *J Bone Joint Surg* 1972; 54-A: 1561-1564.
5. **Epstein HC, Wiss DA.** Traumatic anterior dislocation of the hip. *Orthopaedics*. 1985; 8: 130-134.
6. **Erb RE, Steele JR, Nance EP, Edwards JR.** Traumatic anterior dislocation of the hip: Spectrum of plain film and CT findings. *Am J Roentgenol* 1995; 165: 1215-1219.
7. **Mirovsky Y, Fischer S, Hendel D, Halperin N.** Traumatic anterior dislocation of the hip joint with fracture of the acetabulum: a case report. *J Trauma* 1988; 28: 1597-1599.
8. **Nerubay J.** Traumatic anterior dislocation of hip joint with vascular damage. *Clin Orthop* 1976; 116: 129-132.
9. **Scudese VA.** Traumatic anterior hip redislocation – A case report. *Clin Orthop* 1972; 88: 60-62.
10. **Sherlock DA.** Traumatic anterior dislocation of the hip. *J Trauma* 1988; 28: 411-413.