



Primary haemangiopericytoma of the tibia. Treatment by en bloc resection and bone transportation. A case report

Ippokratis HATZOKOS, Ioannis GIGIS, Eirini IOSIFIDOU, Androniki DRAKOU, John POURNARAS

From the 1st Orthopaedic Department, Aristotelian University of Thessaloniki, Greece

INTRODUCTION

Haemangiopericytomas (HPCs) are rare vascular tumours arising from pericytes, which are contractile cells that spiral around capillary walls. Therefore HPCs have a wide distribution in both soft tissue and skeletal system, with the latter being the most unusual occurrence. Sixty-three cases of osseous HPC have been reported in the available literature, only four of them located in the tibia (7, 12, 25, 26). The prognosis of the tumour behaviour is still not feasible and it has the potential to demonstrate a highly malignant course.

In this paper, a new case of primary HPC located in the proximal tibia, with a unique radiographic appearance, is presented. It was treated with en bloc surgical excision and bone transportation based on the principles of distraction osteogenesis.

CASE REPORT

A 66-year-old Caucasian female was admitted in our department with a lesion located in the upper third of her left tibia. She had a four-year history of proximal tibial "swelling" and recalled two episodes of "inflammation" in the past which subsided with rest and antibiotic treatment.

At presentation, physical examination revealed a moderately tender bony mass at the anteromedial aspect of her left tibia with no signs of inflammation. Knee motion was unimpaired.

Anteroposterior and lateral radiographs of her left tibia showed a heterogeneously dense lesion with a geographic pattern of destruction, extending from just distal to the tibial tuberosity, as far as 10 cm distally. Periosteal buttressing co-existed (fig 1).

CT scan of the tibia revealed a strongly and heterogeneously enhancing mass which occupied the medullary cavity without breaking through the cortex. Periosteal reaction was present with no signs of soft tissue infiltration.

On the technetium bone scan, the mass appeared as a solitary "hot" lesion, due to the increased radioisotope uptake. CT scan of the lungs revealed no abnormal findings.

Laboratory results (Hb, Hct, ESR, SGOT, SGPT, alkaline phosphatase, serum calcium and serum glucose) were within normal limits.

A biopsy of the tumour was carried out. Histologically the tumour was characterised by a

■ Ippokratis Hatzokos, MD, Assistant Professor of Orthopaedics.

■ Ioannis Gigis, MD, Orthopaedic Surgeon.

■ Eirini Iosifidou, MD, Orthopaedic Surgeon.

■ Androniki Drakou, MD, Orthopaedic Surgeon.

■ John Pournaras, MD, Professor of Orthopaedics.

Correspondence : Ippokratis Hatzokos, Assistant Professor of Orthopaedics, Th. Sofouli 33, 54655 Thessaloniki, Greece.
E-mail : ipphatz@yahoo.gr.

© 2005, Acta Orthopædica Belgica.

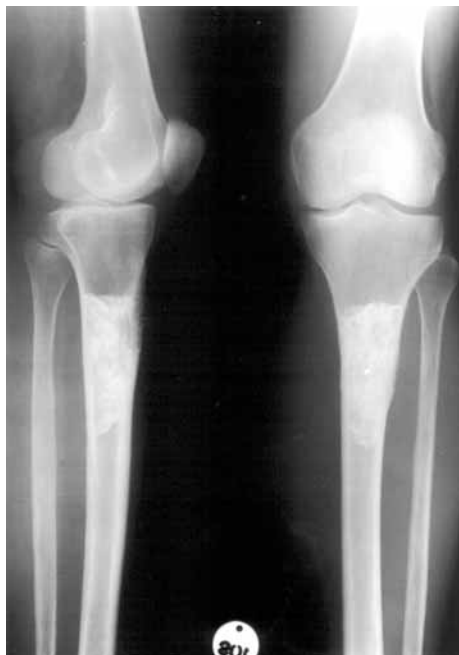

Fig. 1. — Radiographic appearance of HPC of the left tibia on admission.

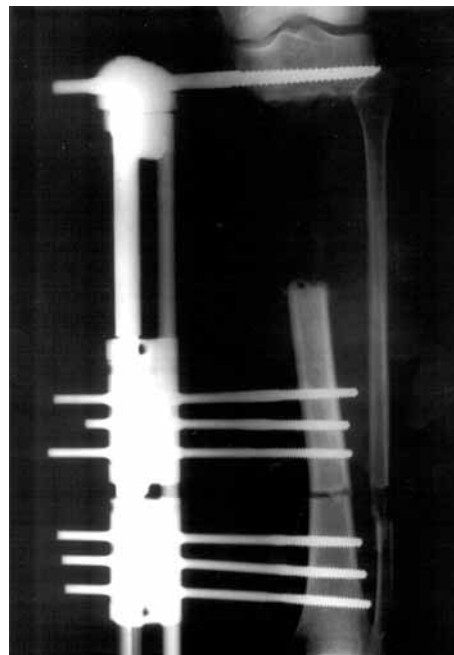


Fig. 2. — Postoperative radiograph showing the size of the osseous gap and the site of the distal osteotomy performed; application of the LRS (Orthofix) external fixator.

monomorphic population of abundant polygonal or spindle-shaped cells, packed around branching vascular channels. The vascular origin of the tumour was evident, with islands of osteoid, mainly fibrous tissue. No cartilaginous elements were present. Moderate mitotic activity and nuclear atypia were observed. Tumoral necrosis and haemorrhage were absent.

Immunostains performed on the specimen showed positive staining of the tumour cells for SMA (smooth muscle actin), but negative staining for S-100 protein and desmin. On the basis of clinical, histological and immunohistochemical observations it was concluded that the tumour was a primary Grade 2 haemangiopericytoma of the tibia according to the Tang *et al* grading system (31).

En bloc surgical excision was carried out after application of an external fixator with a sliding segment (Orthofix LRS External Device, Bussolengo, Verona, Italy) to allow bone transportation (fig 2).

A bone block 10 cm in length and 4 cm in width was excised from the proximal tibia, containing the

tumour, which measured 7 cm in length and 3.9 cm in width. The tumour, a greyish soft and fleshy mass, was occupying the medullary canal extending as far as the periosteum, which was found strikingly sclerotic. Surgical margins were free of disease.

Through a separate incision, a subperiosteal osteotomy at a level 10 cm distal to the lower margin of the tibial defect was performed. On the 10th post-operative day bone transportation commenced based on the principles of distraction osteogenesis.

Repeated histological and immunohistochemical observations performed on the operative specimen confirmed that the tumour was a Grade 2 primary haemangiopericytoma of bone. Because of the satisfactory extent of the surgical excision, the patient did not receive any form of adjuvant therapy. The osseous defect was progressively replaced with new bone formation (fig 3), but 18 months after the initial operation, delayed union occurred at the docking site of the transported bone segment, on the proximal tibia. This was treated by bone grafting and the application of a dynamised external fix-

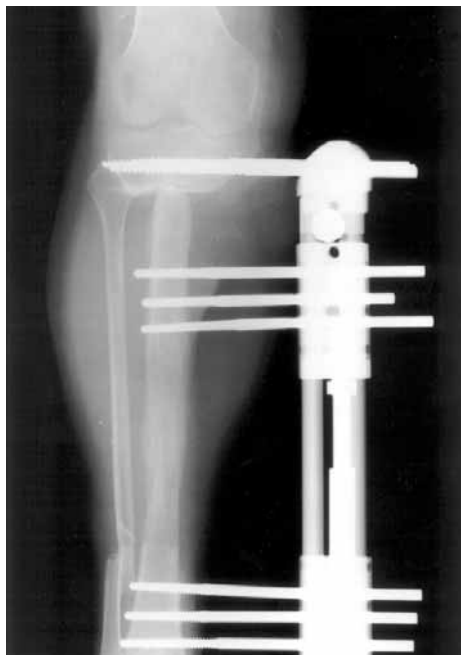


Fig. 3. — Sixteen weeks postoperatively, the osseous defect was progressively replaced by new bone formation.

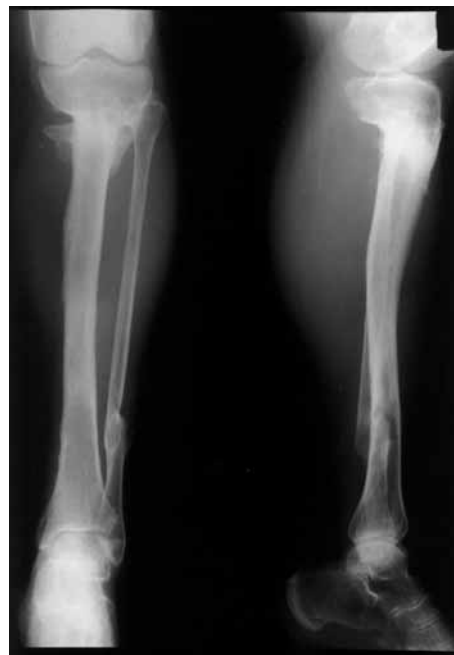

Fig. 4. — Twenty-six months after the initial operation and six months after bone grafting of the docking site, union occurred and the patient was free to fully weight-bear.

ator. Six months later union occurred and the patient was allowed full weight bearing (fig 4).

The follow-up at ten years included antero-posterior and lateral radiographs of the tibia, bone scintigraphy and baseline blood testing. The possible metastatic sites i.e. the lungs and brain were checked by CT and MRI scan respectively. All investigations excluded local recurrence or metastatic spread ten years after the original operation and fourteen years after the tumour had been initially diagnosed.

DISCUSSION

Primary HPC is a vascular tumour arising from the contractile elongated cells which surround capillaries. Primary HPC commonly occurs in soft tissues (2.5% of all soft tissue tumours), while primary osseous HPC is very rare, comprising only 0.1% of all primary bone tumours (3, 18, 31). The latter was first described by Stout and Murray in 1942 (30).

In 1988, Tang *et al* (31) reviewed 45 cases of osseous HPC. Since then, 18 more cases of osseous HPC have been reported in the available literature, only four of them located in the tibia (table I).

The commonest site of origin appears to be the pelvis, followed by the femur. Other less usual sites are the skull, the vertebrae and the chest wall (table II).

A high frequency of bone metastases from cranial HPC has also been reported and it is important that cranial disease must be excluded before one can accept the diagnosis of a primary HPC (9, 11, 13).

Patients' ages range from 8.5 to 90 years in the osseous type and there appears to be a peak incidence in the third and fourth decades. Although Tang *et al* (31) reported in 1988 a clear sex predominance with a male to female ratio of 1.8 to 1.0, we found no significant difference in sex distribution when 18 new cases were included. The soft tissue type has also been reported in infants and children, the infantile type showing a more benign behaviour (4, 24, 32).

Table I. — Patient data

Author(s) – Year	Case #	Sex	Location	N of cases
Tang <i>et al</i> (1988) (31)	1-45	28 M, 16 F, 1 undetermined	Pelvis	12
			Femur	9
			Vertebrae	5
			Mandible	4
			Humerus	4
			Skull	3
			Chest Wall	3
			Clavicle	1
			Scapula	1
			Fibula	1
			Metacarpal	1
			Calcaneus	1
			Temporal	1
			Birgalis <i>et al</i> (1990) (in 12)	46
Benz <i>et al</i> (1990) (2)	47	M	Chest Wall	1
Sellke <i>et al</i> (1991) (29)	48	F	Chest Wall	1
Cosentino <i>et al</i> (1993) (in 12)	49	F	Skull	1
Chin <i>et al</i> (1993) (in 12)	50	F	Temporal	1
Zornig <i>et al</i> (1993) (33)	51	F	Chest Wall	1
Rao <i>et al</i> (1994) (23)	52	M	Femur	1
Lin <i>et al</i> (1996) (in 12)	53	F	Vertebrae (axis)	1
Heymans <i>et al</i> (1997) (10)	54	F	Pelvis	1
Sahin- Akyar <i>et al</i> (1997) (26)	55	F	Tibia	1
Sabo <i>et al</i> (1999) (25)	56	M	Tibia	1
Juan <i>et al</i> (2000) (12)	57	M	Tibia	1
Durr <i>et al</i> (2000) (7)	58	F	Tibia	1
Mahnken <i>et al</i> (2002) (15)	59-63	2F	Femur	2
		1M, 1F	Pelvis	2
		F	Skull	1
Current report	64	F	Tibia	1

Oncogenic osteomalacia secondary to HPC has been reported (1, 19) as well as a paraneoplastic syndrome associated with HPC (5). There are suggestions that HPC tumour cells produce insulin-like growth factor (IGF II) and that this in turn stimulates their proliferation by autocrine mechanisms. In eight reported cases severe hypoglycaemia co-existed with malignant HPC, which was reversed after removal of the tumour itself or the metastases (8, 21). No evidence of hypoglycaemia was determined following repeated blood testing in our case.

Radiographic presentation is variable and is hardly of any prognostic value. To our knowledge, the heterogeneous dense appearance of our case is unique, whereas an ill-defined or a well-circum-

scribed area of radiolucency is the main appearance of osseous HPC (18, 31). Periosteal reaction as in our case may be present as well as cortical breakthrough (6, 12, 26, 31).

CT scan seems to add little to plain radiographs (12, 26).

The histological findings in our case were similar to those reported in literature. Histologically the tumour comprised of a monomorphic population of polygonal to spindle-shaped cells aggregated around branched capillaries with the characteristic staghorn-like configuration. Islands of osteoid-like material of fibrous consistency were present. Mitotic activity and nuclear atypia were moderate but they seem to be quite unreliable prognostic factors of the tumour's behaviour (3, 12, 14, 17, 22, 26, 27,

Table II. — Skeletal distribution of osseous hemangiopericytoma (64 cases)

Location	Number
Pelvis	15
Femur	12
Skull	7
Vertebrae	6
Chest Wall	6
Tibia	5
Mandible	4
Humerus	4
Clavicle	1
Scapula	1
Fibula	1
Metacarpal	1
Calcaneus	1
Total	64

32). Necrotic areas within the tumour are usually not present and this also applied to our case.

Immunostains performed on our surgical resection specimens showed positive staining of tumour cells for smooth muscle Actin, whereas S-100 protein and desmin were not expressed within the lesion.

It is still not possible to predict the tumour's behaviour. Suggestions made in order to estimate the malignant potential of HPC include: 1) patient's age (the infantile type has a better prognosis), 2) site of origin: retroperitoneal and meningeal tumours are associated with higher local recurrence rates compared to tumours at extremity anatomic sites, 3) presence of radiographic cortical erosion and/or periosteal reaction is associated with malignant course, 4) histological findings of increased mitotic activity, nuclear atypia, hypercellularity and/or polymorphism, presence of focal necrosis or haemorrhage within the tumour, are supposed to predict malignancy. Nevertheless most of them are at least locally aggressive (3, 6, 10, 12, 14, 24, 27, 28, 32). It is concluded that classification into benign and malignant is of no prognostic value, a view shared by Marcial-Rojas since 1960 (16).

Therefore it is believed that the treatment should be initially aggressive. For resectable tumours, most authors believe that adequate surgery alone

(wide local or radical resection) and long-term follow up would suffice. As for others, adequate surgery combined with postoperative radiation therapy is the treatment of choice, whereas only few authors believe in the effectiveness of multimodal therapy including chemotherapy. As for unresectable tumours or disseminated disease, there is a role for palliative radiotherapy, but adjuvant radiotherapy and/or chemotherapy seem non-effective in controlling local recurrence or metastatic disease. The only form of HPC (osseous or soft tissue) where documented chemoresponsiveness has been reported is the infantile type. Some authors report the use of preoperative superselective vascular embolisation for controlling the intraoperative haemorrhage during resection of vascular HPCs (5-7, 12, 14, 20, 22, 24, 26, 31).

We elected to treat our patient with wide local resection (en bloc). Because the tumour was resected with its entire anatomical compartment and the surgical margins were free of disease, no form of adjuvant therapy was considered necessary for this case.

Bone transportation enabled the wide resection (10 cm) and resulted in the restoration of the tibial length and excellent function of the limb.

Discussion involving survivorship is based largely on the experience of soft tissue HPC and it is only assumed that osseous HPC would behave in the same way. Recurrence rate, including local or distant metastases varies from 12 to 78%. The commonest site of metastases seems to be the lung, followed by the chest wall, the brain and bowel, via haematogenous or lymphatic spread. The five-year survival rate varies from 43 to 75% (6, 8, 12, 14, 27, 28, 31, 32). Follow-up should be frequent during the first 3 years (at 6-monthly intervals) and yearly thereafter. No local recurrence or distal metastasis was detected in our case at ten-year follow up.

REFERENCES

1. **Baronofsky SI, Kalbhen CL, Demos TC, Sizemore GW.** Oncogenic osteomalacia secondary to a hemangiopericytoma of the hip: case report. *Can Assoc Radiol J* 1999; 50: 26-28.
2. **Benz G, Schäfer K, Daum R.** Tumeurs des côtes chez l'enfant. *Chir Pédiatr* 1990; 31: 152-156.

3. **Chhieng D, Cohen JM, Waisman J et al.** Fine-needle aspiration cytology of hemangiopericytoma : A report of five cases. *Cancer* 1999 ; 87 : 190-195.
4. **Cole JC, Naul LG.** Intracranial infantile hemangiopericytoma. *Pediatr Radiol* 2000 ; 30 : 271-273.
5. **Derakhshani P, Neubauer S, Braun M et al.** Giant retroperitoneal hemangiopericytoma with paraneoplastic gynecomastia. Case report and literature review. *Urol Int* 1999 ; 62 : 332-335.
6. **Dunlop J.** Primary hemangiopericytoma of the bone. Report of two cases. *J Bone Joint Surg* 1973 ; 55-B : 854-857.
7. **Durr HR, Nerlich A, Lienemann A et al.** Malignant hemangiopericytoma of the bone. *Langenbecks Arch Surg* 2000 ; 385 : 207-212.
8. **Grunenberger F, Bachellier P, Chenard MP et al.** Hepatic and pulmonary metastases from a meningeal hemangiopericytoma and severe hypoglycemia due to abnormal secretion of insulin-like growth factor : a case report. *Cancer* 1999 ; 85 : 2245-2248.
9. **Guthrie BL, Ebersold MJ, Scheithauer BW, Shaw EG.** Meningeal hemangiopericytoma : histopathological features, treatments and long-term follow up of 44 cases. *Neurosurgery* 1989 ; 25 : 514-522.
10. **Heymans O, Gebhart M, Larsimont D et al.** Malignant hemangiopericytoma of the pelvis : treatment using internal hemipelvectomy. *Acta Orthop Belg* 1997 ; 63 : 40-42.
11. **Jaaskelainen J, Servo A, Haltia M et al.** Intracranial hemangiopericytoma : radiology, surgery, radiotherapy and outcome in 21 patients. *Surg Neurol* 1985 ; 23 : 227-236.
12. **Juan CJ, Huang GS, Hsueh CJ et al.** Primary hemangiopericytoma of the tibia : MR and angiographic correlation. *Skeletal Radiol* 2000 ; 29 : 49-53.
13. **Lafond-Kim GM, Disler DG, Hou J et al.** Osseous hemangiopericytomas of unsuspected intracranial origin. *Skeletal Radiol* 1998 ; 27 : 98-102.
14. **Lim JK, Teston L, Pennington DG, May J.** Hemangiopericytoma of the hand : a literature review and case study. *J Hand Surg* 1992 ; 17-A : 1051-1055.
15. **Mahnken AH, Tacke J, Wolter P et al.** Cross-sectional imaging of primary osseous hemangiopericytoma. *Eur Radiol* 2002 ; 12 : 85-89.
16. **Marcial-Rojas RA.** Primary hemangiopericytoma of bone : review of the literature and report of the first case with metastases. *Cancer* 1960 ; 13 : 308-311.
17. **Migliorini L, Sandri S, Schiaffino E, Cazzaniga MG.** Benign hemangiopericytoma of the bladder : description of a case and review of the literature. *Pathologica* 2000 ; 92 : 89-93.
18. **Mirra JM, Tang JS, Gold RH.** Hemangiopericytoma In : Mirra JM. *Bone Tumors : Clinical, radiologic and pathologic correlations*. Vol 2. Lea & Febiger, Philadelphia, London, 1989 : pp 1436-1453.
19. **Ohashi K, Ohnishi T, Ishikawa T et al.** Oncogenic osteomalacia presenting as bilateral stress fractures of the tibia. *Skeletal Radiol* 1999 ; 28 : 46-48.
20. **Pandey M, Kothari KC, Patel DD.** Haemangiopericytoma : current status, diagnosis and management. *Eur J Surg Oncol* 1997 ; 23 : 282-285.
21. **Pavelic K, Spaventi S, Gluncic V et al.** The expression and role of insulin-like growth factor II in malignant hemangiopericytomas. *J Mol Med* 1999 ; 77 : 865-869.
22. **Perugia D, Basile A, Massoni C, Barletta V.** Hemangiopericytoma in the distal third of the arm. *Int Orthop* 1999 ; 23 : 184-186.
23. **Rao CR, Naresh KN, Pattabhiraman V et al.** Hemangiopericytoma of the bone- a case report. *Indian J Cancer* 1994 ; 31 : 264-267.
24. **Rodriguez-Galindo C, Ramsey K, Jenkins JJ et al.** Hemangiopericytoma in children and infants. *Cancer* 2000 ; 88 : 198-204.
25. **Sabo D, Bernd L, Ewerbeck V et al.** Lokale Behandlung primär maligner Knochentumoren. Intraoperative extrakorporale Bestrahlung und Replantation. *Unfallchirurg* 1999 ; 102 : 580-588.
26. **Sahin-Akyar G, Fitoz S, Akpolat I et al.** Primary hemangiopericytoma of bone located in the tibia. *Skeletal Radiol* 1997 ; 26 : 47-50.
27. **Saleh HA, Haapaniemi J.** Aspiration biopsy cytology of malignant hemangiopericytoma metastatic to the lungs. Cytomorphologic and immunocytochemical study of a case. *Acta Cytol* 1997 ; 41 (Suppl 4) : 1265-1268.
28. **Sawh RN, Lele SM, Borkowski J et al.** Fine-needle aspiration cytology of hemangiopericytoma : Report of two cases. *Diagn Cytopathol* 2000 ; 23 : 187-191.
29. **Sellke FW, Laszewski MJ, Robinson RA et al.** Hemangiopericytoma of the sternum. *Arch Pathol Lab Med* 1991 ; 115 : 242-244.
30. **Stout AP, Murray MR.** Hemangiopericytoma : a vascular tumor featuring Zimmerman's pericytes. *Ann Surg* 1942 ; 116 : 26-33.
31. **Tang JSH, Gold RH, Mirra JM, Eckardt J.** Hemangiopericytoma of the bone. *Cancer* 1988 ; 62 : 848-859.
32. **Templeton PA, Gordon DJ, O'Hara MD.** Infantile haemangiopericytoma of the hand. *J Hand Surg* 1996 ; 21-B : 121-123.
33. **Zornig C, Langwieler TE, Weh HJ, Schroder S.** Malignant hemangiopericytoma of the chest wall. *Eur J Surg Oncol* 1993 ; 19 : 87-91.