

CASE REPORT

Pseudomalignant myositis ossificans of the wrist causing compression of the ulnar nerve and artery. A case report

Tufan KALELI, Aytun TEMİZ, Hülya ÖZTÜRK

Myositis ossificans (MO) is a condition characterised by focal, benign and self-limited idiopathic heterotopic bone formation. It is extremely rare in the hand and wrist and may lead to concomitant nerve compression. Because of the rare incidence of pseudomalignant MO at the wrist and hand, we found it of interest to report a case of this condition localised to the wrist.

A 31-year-old female patient presented with swelling and pain of her left wrist. The physical examination findings, magnetic resonance imaging and Tc-99m bone scan suggested acute osteomyelitis or a tumoral condition. Incisional biopsy and pathological examination was done. The microscopic findings confirmed that the lesion was pseudomalignant MO. The lesion was removed totally and decompression of the ulnar nerve and artery was achieved. The patient regained full asymptomatic range of motion of all digits and wrist and the numbness of the fourth and fifth digits had subsided at follow-up five months later.

Because of the rare incidence of myositis ossificans at the wrist (6), we found it of interest to report a case of pseudomalignant MO at the wrist.

CASE REPORT

A 31-year-old female patient, who had no history of major trauma, presented with swelling and pain of the left wrist that had progressively worsened over a two-month period. Physical examination disclosed a palpable mass located at the volar and ulnar aspect of the wrist, with pain and tenderness over the mass, numbness of the fourth and fifth digits and limited and painful wrist flexion. The most striking roentgenographic finding at the left wrist was soft-tissue calcification on the volar aspect (fig 1). Magnetic resonance imaging [MRI] showed a soft tissue calcification that suggested a malignant soft tissue tumour (fig 2). A Tc-99m

INTRODUCTION

Myositis ossificans (MO) is a condition characterised by self-limited, focal, non-neoplastic heterotopic formation of mature lamellar bone within muscle or soft tissue (5). The pathogenesis of myositis ossificans is not fully understood, although it is associated with certain clinical situations such as soft tissue trauma. However, in some cases, localised deposits of heterotopic bone may develop without an antecedent trauma. These lesions are termed 'pseudomalignant myositis ossificans' and consist of rapidly proliferating mesenchymal cells which differentiate into osteoprogenitor cells.

From the University of Uludağ, Department of Orthopaedic Surgery¹ and Pathology Department², Bursa, Turkey.

Tufan Kaleli, Professor and Chairman of the Hand and Microsurgery Division, University of Uludağ, Faculty of Medicine, Department of Orthopaedic Surgery.

Aytun Temiz, Resident, University of Uludağ, Faculty of Medicine, Department of Orthopaedic Surgery.

Hülya Öztürk, Resident, University of Uludağ, Faculty of Medicine, Department of Orthopaedic Surgery.

Correspondence and reprints : Tufan Kaleli, University of Uludağ, Faculty of Medicine, Department of Orthopaedic Surgery, 16059, Görükle, Bursa, Turkey.

E-Mail : kaleli@uludag.edu.tr.

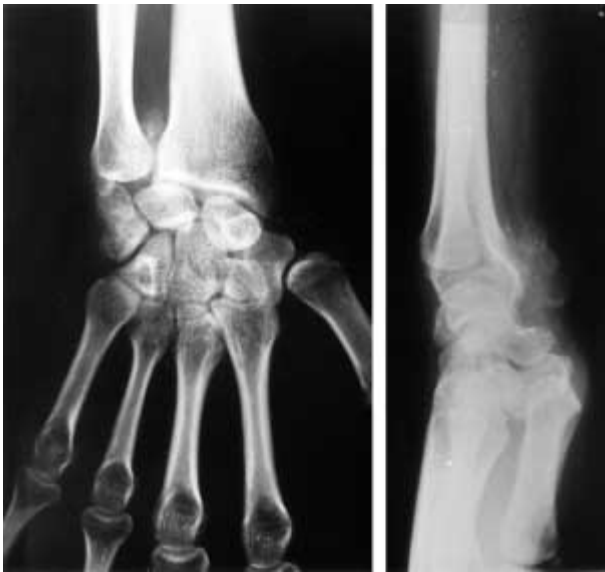


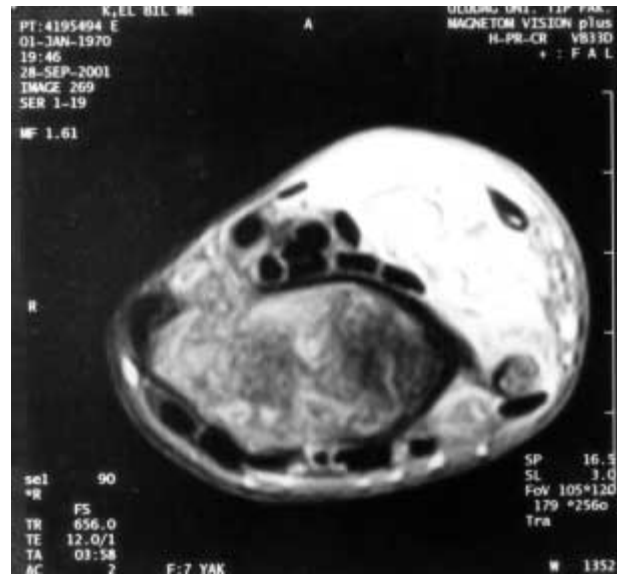
Fig. 1. — AP and lateral radiographs of the wrist

bone scan showed an increased uptake that suggested acute osteomyelitis or a tumoral condition. Other parts of the skeletal system were normal.

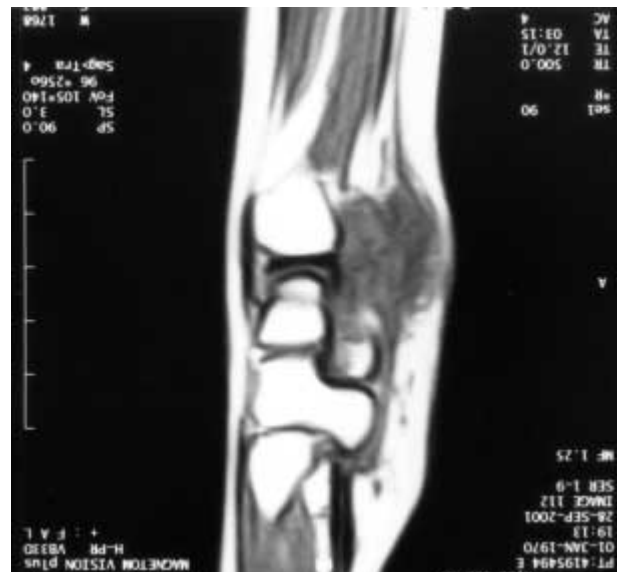Incisional biopsy and pathological examination of the specimen was done. Microscopically, the periphery of the lesion was composed of relatively well-formed trabeculae of mature bone and the centre of the lesion was composed of compact fibroblasts and osteoblasts and osteoid material (fig 3). The lesion was removed totally. Surgical findings were correlated with the MRI findings suggesting compression of ulnar nerve and artery. There were two grooves corresponding to the ulnar nerve and artery over the mass which was surgically excised. There was no evidence of recurrence at follow-up five months later. The patient had a full asymptomatic range of motion of all digits and wrist and the numbness of fourth and fifth digits had subsided.

DISCUSSION

Extraskelletal bone formation may occur in tendons, fasciae, periosteum, subcutaneous fat or organs such as kidney or breast (8). MO refers more specifically to the formation of bone in muscle tissue. MO is one of four different types of benign idiopathic heterotopic bone formation. These are



a



b

Fig. 2. — Magnetic resonance imaging of the pseudomalignant myositis ossificans showing compression of the ulnar nerve and artery especially in coronal cross-section of the lesion.

traumatic MO, fibrodysplasia ossificans progressiva, MO associated with paraplegia and pseudomalignant MO. Traumatic MO, which develops after injury, is the most common variety. However, radiological and pathological findings are similar in each condition (6).

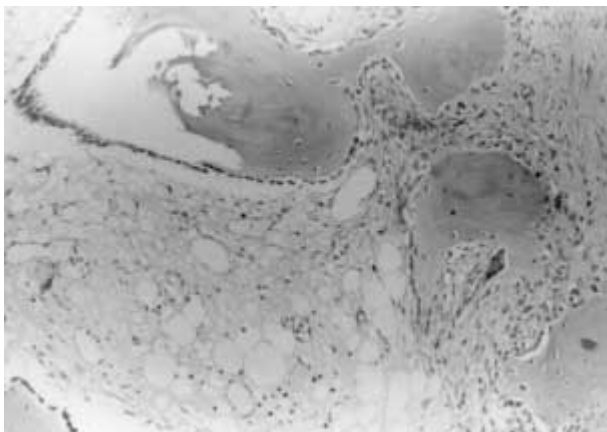


Fig. 3. — Microscopic findings of the lesion. Well-formed trabeculae of mature bone, compact fibroblasts, osteoblasts and osteoid material are seen.

The characteristic clinical presentation is a rapid onset of pain, a palpable mass, oedema, joint contractures and decreased range of motion (4). Severe pain and paresthesia may be present if there is concomitant nerve compression (2). Severe forms of heterotopic bone formation such as fibrodysplasia ossificans progressiva, may lead to death (3). One of the most important clinical features of pseudomalignant MO is the similarities with certain malignant conditions that involve extraskeletal ossification such as extrasosseous osteosarcoma (5).

The clinical entity described here is pseudomalignant MO, which is a rare soft tissue lesion that involves the limbs in 80% of cases and most commonly affects individuals in the second and third decade of life (1). It has been well described in other locations but it is extremely rare in the hand and wrist (2, 4). Diagnostic confusion may arise with myositis ossificans, especially early in the course of the disease. There are several important features that are helpful in distinguishing pseudomalignant myositis ossificans. Histologically, the 'zone phenomenon' with three distinct areas, is the most useful distinction between pseudomalignant myositis ossificans and a soft tissue sarcoma. It is important to note that MO is a membranous ossifi-

cation in contrast to other bizarre parosteal osteochondromatous lesions.

Appropriate treatment depends on the individual case. Because of the self-limiting and benign characteristics of the lesion, a waiting period of a few months is acceptable to allow time for the regression of the lesion (7). Because most cases of myositis ossificans in the hand present with intractable pain and limitation of function, a more aggressive approach may be required. Recurrence is unusual after complete excision of the lesion (7, 9).

To summarise, pseudomalignant MO is an extremely rare condition in the hand and wrist and may lead to concomitant nerve compression (6). Because of some histologic findings such as rapid proliferation process and some radiologic characteristics such as periosteal reaction of bone, this lesion is termed 'pseudomalignant'.

REFERENCES

1. **Ackerman LV.** Extrasosseous localized nonneoplastic bone and cartilage formation (so-called myositis ossificans). Clinical and pathological confusion with malignant neoplasms. *J Bone Joint Surg* 1958 ; 40-A : 279-298
2. **Bulstrode C, Helal B, Revel P.** Pseudomalignant osseous tumour of soft tissue. *J Hand Surg* 1984 ; 9-B : 345-346
3. **Cohen RB, Hahn GV, Tabas JA.** The natural history of heterotopic ossification in patients who have fibrodysplasia ossificans progressiva. *J Bone Joint Surg* 1993 ; 75-A : 215-219
4. **DeSmet L, Vercauteren M.** Fast-growing pseudomalignant osseous tumour (myositis ossificans) of the finger. A case report. *J Hand Surg* 1984 ; 9-B : 93-94
5. **Kaplan FS, Gannon FH, Hahn GV, Wolner N, Prauner R.** Pseudomalignant heterotopic ossification. *Clin Orthop* 1998 ; 346 : 134- 140
6. **Kusuma S, Lourie GM, Lins RE.** Myositis ossificans of the hand. *J Hand Surg* 1999 ; 24-B : 128-130
7. **Merchan ECR, Sanchez-Herrera S, Valdozo DA, Gonzalez JM.** Circumscribed myositis ossificans : report of nine cases without history of injury. *Acta Orthop Belg* 1993 ; 59 : 273-277
8. **Puzas JE, Miller MD, Roiser RN.** Pathologic bone formation. *Clin Orthop* 1989 ; 245 : 269-281
9. **Schütte HE, Van der Heul RO.** Pseudomalignant, nonneoplastic osseous soft-tissue tumours of the hand and foot. *Radiology* 1990 ; 176 : 149-153