



## Can we predict the natural course of femoroacetabular impingement ?

Emmanuel A. AUDENAERT, Ian PEETERS, Stefaan VAN ONSEM, Christophe PATTYN

*From Gent University Hospital, Gent, Belgium*

We conducted a multivariate regression analysis (including both radiographic and activity related variables) in patients with osteoarthritis of the hip and structural changes related with femoroacetabular impingement.

The purpose of this study was to investigate whether the age at which total hip arthroplasty may have to be performed, can be predicted in patients with femoroacetabular impingement (FAI).

In 121 patients with FAI-related osteoarthritis, radiographic variables describing FAI-related parameters were obtained and the patients were questioned about their activity during early adulthood by means of the validated Baecke *et al* questionnaire.

None of the variables significantly correlated with the final outcome parameter : age at surgery. As expected, based on the low correlation ratios of the different parameters investigated, a multiple-regression model was not accurate enough to allow any prediction on the natural course of FAI.

We found that it is difficult to accurately predict the age at which a patient with FAI will develop early osteoarthritis. From our findings it appears that a hip with FAI is not always prone to early end-stage osteoarthritic degeneration, not even in patients with a high level of physical activity. Hence, considering the high prevalence of FAI-related radiographic findings, we conclude that not every radiographic abnormality requires treatment.

**Keywords :** femoroacetabular impingement ; hip osteoarthritis, total hip arthroplasty.

## INTRODUCTION

Although femoro-acetabular impingement (FAI) has only recently been postulated as a key mechanical cause in the development of early osteoarthritis (OA) of the hip, it has already become a major issue, as evidenced by the steadily increasing literature on the subject (19). FAI is a mechanical hip disorder defined as early and/or repetitive contact between the acetabular rim and the proximal femur, potentially resulting in damage to the hip joint cartilage and labrum. Depending on the clinical and radiographic findings, two types of impingement are distinguished (38). Pincer-type impingement is

---

■ Emmanuel A. Audenaert, MD, Junior Staff Member.

■ Ian Peeters, MB, Medicine Student.

■ Stefaan Van Onsem, MB, Medicine Student.

■ Christophe Pattyn, MD, PhD, Senior Staff Member.

*Department of Orthopaedic Surgery, Physical Medicine and Rehabilitation, Gent University Hospital, De Pintelaan 185, 9000 Gent, Belgium.*

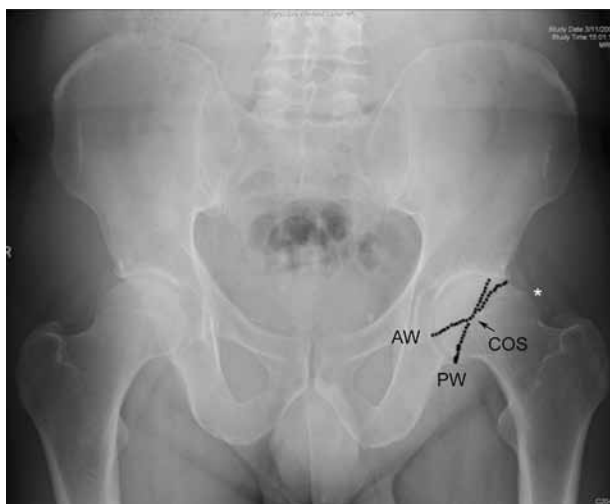Correspondence : Emmanuel Audenaert, Department of Orthopaedic Surgery, Physical Medicine and Rehabilitation, Gent University Hospital, De Pintelaan 185, 9000 Gent, Belgium. E-mail : emmanuel.audenaert@ugent.be

© 2011, Acta Orthopædica Belgica.

---

*No support, financial or other, has been received for writing this manuscript.*

*The process of data acquisition and analysis as well as the format and structure of the informed consent and information brochure for the study participants, has been approved by the Ethical Committee of the Ghent University Hospital, Belgium*



**Fig. 1.** — A standard AP radiograph of a patient with FAI related OA shows a cam-type deformity (asterix) as well as a positive cross over sign (COS) indicating a mixed-type FAI. PW : posterior acetabular wall ; AW : anterior acetabular wall.

described as the acetabular cause of FAI and is characterised by focal or general over-coverage of the femoral head resulting in early abutment with the femoral neck at the end-range of motion. Cam-type impingement is the femoral cause of FAI and is characterised by the presence of an a-spherical extrusion at the femoral head-neck junction with the potential of intrusion into the joint with subsequent risk of delamination and abrasion of the acetabular cartilage. Most patients have a combination of these two mechanisms (4) (Fig. 1) and the prevalence of these lesions has been reported to be as high as 17% (14).

A relationship between the two types of FAI and the development of OA has been confirmed in multiple studies. Typical FAI-related lesions have been observed intra-operatively in FAI and OA related surgery, and a significant relationship has been reported between radiographic parameters specific of FAI and the presence of OA (1,8,17,37,38,40,42).

Despite this growing evidence of a link between FAI and OA, the natural course of the condition remains unpredictable. It is unclear which patients are prone to developing end-stage OA. Can they reliably be identified before OA develops and, if so, is corrective surgery indicated or not? In the litera-

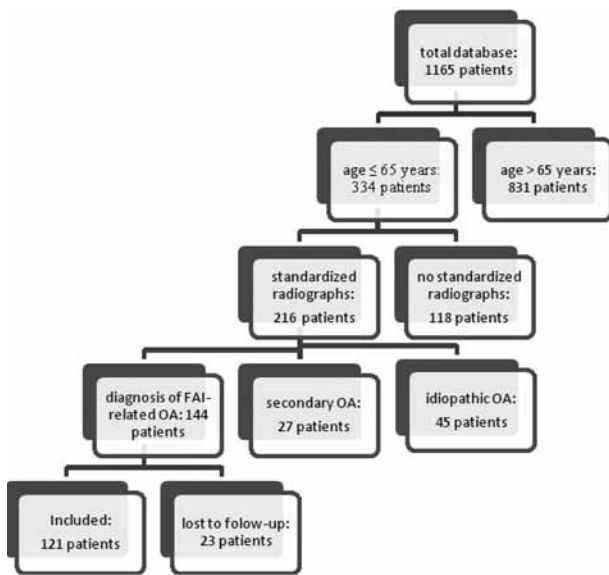
ture, aberrant morphological features and patient-activity levels have both been suggested as potential predictors of progressive arthritic changes in FAI (3,11,17,19,21,22). The present study was designed to establish whether the predictive accuracy for osteoarthritic changes in FAI progressing to end-stage OA can be improved. This would provide a more definite indication for close follow-up or surgical need in patients with no or mild clinical complaints.

We hypothesized that a relation might exist between the morphology of FAI measured on radiographic images, the level of habitual patient activity and the rate of progression of OA. We investigated whether the age at which total hip arthroplasty (THA) will have to be performed, can reliably be predicted based on a multivariate regression analysis including both radiographic and activity-related variables.

## PATIENTS AND METHODS

We analysed the digitised radiographic images of 1,165 patients who underwent THA at our department between 2005 and 2009. From this database, 334 patients with a diagnosis of early OA at an arbitrary maximum age of 65 were selected. Of these patients, only 216 patients whose radiographs met the standardised criteria as described by Tannast *et al.* could be retained (38). We included only radiographs with neutral tilt, in which the distance from the tip of the coccyx to the symphysis was between 0 to 20 mm (18). An antero-posterior (AP) pelvic view as well as a cross-table lateral view of the affected hip were required for inclusion. We excluded all patients in whom hip arthroplasty had been performed for a known secondary reason such as trauma or developmental deformities (prior ipsilateral hip surgery or evidence of post-traumatic deformity, primary OA, Legg-Calvé-Perthes disease, osteonecrosis, slipped capital femoral epiphysis or hip dysplasia). Of the remaining 189 patients, 144 met the criteria for FAI-related OA, defined by an angle greater than 55° on a cross-table lateral view or a positive cross-over sign on an AP pelvic view (26,32).

Informed consent was obtained from all patients included, as required by the University Hospital Ethics Committee. Patients were questioned about their activity level during early adulthood by means of the validated Baecke *et al.* questionnaire for habitual physical activity



**Fig. 2.** — Stepwise selection procedure used to compile the final study population.

(HPA) (2,5,9,15,16,27,28,33). Twenty-three patients were lost to follow-up, leaving 121 patients for statistical analysis. A schematic overview of the selection procedure used to compile the final study population database is provided in figure 2.

Of the 121 patients 73 were male and 48 were female. Their mean age at surgery was 52.50 years (SD 10.33 years, range : 21 to 65 years) and 55.75 years (SD 7.34 years, range 37 to 65 years) respectively. There was an approximately equal presentation of right (54) and left (67) hips. In 76% of the patients, radiographic evaluation indicated a mixed-type of FAI. The mean  $\alpha$ -angle measured on the cross-table lateral view was 73.54° (SD 15.61°, range : 33.63° to 120.08°).

The mean Baecke *et al.* total activity score was 8.76 (SD 1.07, range : 5-11.25). A complete overview including descriptive and comparative statistics of the obtained measurements in relation to the outcome parameter (age at surgery) is presented in tables I and II.

### Image analysis

All images were obtained with the use of a platform for the storage and management of radiographic images (OrthoWave™ 5.55, Arras, France). The radiographs were analysed for the presence or absence of deformities of the hip by assessing established radiographic variables. All but one variable were measured and interpret-

ed as described by the original author. The triangular index (TI) was originally used to evaluate the presence of a cam deformity by applying a specific cut-off point (13). Instead of this cut-off point, we used the absolute values to determine the height of the cam deformity as a continuous variable. A complete overview of all documented radiographic variables is provided in table III. Data were acquired using the Mimics® software package (Materialise NV, Heverlee, Belgium) which allows for digital analysis including circle-fitting and the measurement of angles and distances. A best-fit-circle procedure was performed where required in the measurement protocol, by placing three randomly chosen points on the contour of the femoral head.

### Activity level

The Baecke *et al* questionnaire for HPA is a recording tool that measures qualitative and quantitative indices. This method is considered to be the gold standard for measuring energy expenditure in free-living individuals (15,28). The questionnaire consists of 16 items, each with a 5-point Likert scale. Three conceptually meaningful factors are distinguished : physical activity at work, sport during leisure time and physical activity during leisure time excluding sport (2). The questionnaire retrospectively evaluates physical activity and the results are grouped under a work index, a sport index and a leisure time index. The total activity score is calculated by summing these three indices.

According to the Netherlands Nutrition Council (25) there are three levels of occupational physical activity : a low level consisting of occupations such as clerical work, driving, shop keeping, teaching, studying, housework, medical practice and all other occupations requiring a university education ; a middle level consisting of occupations such as factory work, plumbing, carpentry and farming ; and a high level consisting of occupations such as dock work and construction work. Durnin and Passmore (7) subdivided sports into three levels of physical activity : a low level for sports such as billiards, sailing, bowling, and golf (average energy expenditure 0.76 MJ/h) ; a middle level for sports such as badminton, cycling, dancing, swimming, and tennis (average energy expenditure 1.26 MJ/h) ; and a high level for sports such as boxing, basketball, football, rugby, and rowing (average energy expenditure 1.76 MJ/h). A sport score was calculated from a combination of the intensity of the sport which was played, the amount of time per week playing that sport, and the proportion of the year in which the sport was played regularly.

Table I. — Descriptive and comparative statistics of the obtained radiographic variables in relation to the outcome parameter (age at surgery)

Radiographic Variable	value	Pearson correlation coefficient with age at surgery	$\alpha$ -level of significance
$\alpha$ -angle (degrees) AP-view	77.92° ± 17.68° (range, 34.56°-113.18°)	.84	.363
$\alpha$ -angle (degrees) cross-lateral view	73.54° ± 15.61° (range, 33.63°-120.08°)	.126	.208
Triangular index AP-view	91.95 ± 16.03 (range, 33.51-118.24)	.134	.143
Triangular index cross-lateral view	103.95 ± 25.50 (range, 30.12-164.08)	-.073	.430
Center edge angle (degrees)	38.84 ± 10.40 (range, 18.64-88.44)	.121	.190
Neck-to-shaft angle (degrees)	129.31 ± 5.41 (range, 117.00-142.28)	.128	.165
Cross-over sign	P = 110 (91%) N = 11 (9%)	n.a.	.281
Ischial spine projection	P = 37 (31%) N = 84 (69%)	n.a.	.695
Horizontal growth plate sign	P = 40 (33%) N = 81 (67%)	n.a.	.250
Herniation pit	P = 25 (21%) N = 96 (79%)	n.a.	.263
Femoral neck exostosis	P = 39 (32%) N = 82 (68%)	n.a.	.271
Posterior wall sign	Lat = 36 (30%) Norm = 15 (12%) Med = 70 (58%)	n.a.	.528

Table II. — Baecke *et al.* activity score measures and their relation to the outcome parameter (age at surgery)

Baecke <i>et al</i> activity score	value	Pearson correlation coefficient with age at surgery	$\alpha$ -level of significance
Total activity score	8.76 ± 1.07 (range, 5-11.25)	-.084	.423
Work index	3.17 ± 0.48 (range, 0.75-4.25)	-.047	.611
Sport index	2.55 ± 0.44 (range, 1.25-3.50)	.054	.557
Leisure index	3.05 ± 0.75 (range, 1.25-4.75)	-.10	.294

This questionnaire was originally described and validated on a Dutch-speaking population, similar to our study population, which means that an understanding bias was unlikely to occur (2,27). The Baecke *et al* questionnaire which is commonly used in epidemiologic studies, has been found to have a good test-retest reliability (16).

### Statistical analysis

Statistical analysis was performed using SPSS software (SPSS 18, Chicago : SPSS Inc). Before inclusion in a multivariate regression model, possible intercorrelation of the variables was investigated by means of the

Pearson correlation coefficient. Dichotomous variables were evaluated using the Mann-Whitney U-test. The level for significance was set at 0.05.

## RESULTS

In the group of continuous variables ( $\alpha$ -angle AP-view,  $\alpha$ -angle cross-lateral view, TI AP-view, TI cross-lateral view, CEA, Neck-to-shaft angle), we only found a significant correlation between the  $\alpha$ -angle and TI ( $p < 0.001$ ) and between the  $\alpha$ -angle measurement on the AP pelvic view and the cross-table lateral view ( $p < 0.001$ ).

Table III. — Documented radiographic variables to define FAI related deformities

Parameter	Definition	Author	Normal Value
$\alpha$ angle	Angle formed by the femoral neck axis and a line connecting the center of the femoral head with the point of beginning asphericity	Nötzli <i>et al</i> (2002) (16)	Less than 55°
Triangular index	Positive if the pathologically increased radius (R) is greater than the normal radius (r) plus 2 mm ; $(R) \geq (r) + 2$ mm	Gosvig <i>et al</i> (2007) (25)	$(R) < (r) + 2$ mm
Cross-over sign	Present if the anterior rim runs more laterally in the most proximal part of the acetabulum and crosses the posterior rim distally	Reynolds <i>et al</i> (1999) (17)	Anterior rim line projects medially to the posterior wall line
Center-edge angle	Angle formed by a line parallel to the longitudinal pelvic axis and by the line connecting the center of the femoral head with the lateral edge of the acetabulum according to Wiberg	Wiberg (1939) (28)	Greater than 25°
Posterior wall sign	A posterior rim medial of the center of the femoral head indicates a deficient posterior acetabular wall, lateral a more prominent posterior wall.	Reynolds <i>et al</i> (1999) (17)	Outline of posterior rim passes approximately through the center of the femoral head
Neck-to-shaft angle	Angle formed by the axis of the femoral neck and the proximal femoral diaphyseal axis	Tönnis and Heinecke (1999) (29)	More than 125° ; less than 135°
Ischial spine projection	The projection of the ischial spine into the pelvic cavity on an AP pelvic radiograph.	Kalberer <i>et al</i> (2007) (15)	No projection
Herniation pit	Round to oval radiolucency surrounded by a thin zone of sclerosis in the proximal superior quadrant of the femoral neck	Pitt <i>et al</i> (1982) (30)	No herniation pit
Horizontal growth plate sign	Epiphyseal scar projects lateral to a best fit circle of the femoral head	Tannast (2007) (2)	Epiphyseal scar projects in the best fit circle
Femoral neck exostosis	A bump projects out of the concave or straight outline of the femoral neck	Dihlmann and Frik (1977) (31, 32)	No bump

None of the continuous variables was significantly correlated with the final outcome parameter : age at surgery. In the group of dichotomous variables (COS, Ischial spine projection, Horizontal growth plate sign, Herniation pit, Femoral neck exostosis, Posterior wall sign), mean age at surgery was significantly higher in case of a positive cross-over sign (pincer-type and mixed-type FAI) in comparison with a pure cam lesion ( $p < 0.05$ ). None of the other dichotomous variables showed a significant variation in age at surgery. As expected, based on the low correlation ratios of the different variables investigated, a multiple-regression model was

not accurate to allow any prediction on the natural course of FAI ( $R^2 : 0.039$ ).

## DISCUSSION

There is growing evidence that radiographic variables and patient-activity levels are potential predictors of progressive osteoarthritic changes in FAI, based on which we can identify patients prone to developing end-stage OA and for whom surgery might be indicated (3,11,17,19,21,22). We investigated whether the age at which THA might be required,

can reliably be predicted based on a multivariate regression analysis including both radiographic and activity-related variables. To our knowledge, there are no studies on the natural course of FAI that have included activity as a predictor of OA progression.

In the literature on FAI, most radiographic variables have been studied independently and some have been suggested to play a role in the development of OA in FAI. Bardakos and Villar (3) showed that two out of many different radiographic variables provide a risk for progression of OA in FAI. By studying two pairs of plain AP pelvic radiographs taken at least ten years apart, they found after logistic regression analysis that the odds ratios for progression were 20.6 (95% CI 3.4 to 34.8) for a medial proximal femoral angle and 10.2 (95% CI 1.0 to 99.8) for the posterior wall sign.

As mentioned above, FAI is mainly considered as a mechanical hip disorder and is defined as early and/or repetitive contact between the acetabular rim and the proximal femur. In addition to the radiographic variables and BMI, we therefore also included the patient activity levels. Before performing a regression analysis we investigated the different continuous variables and found the  $\alpha$ -angle and the TI to be highly interrelated, both on AP pelvic ( $p < 0.001$ ) and on cross-table lateral view ( $p < 0.001$ ). Although this is consistent with the findings of Gosvig *et al* (13), who found an odds ratio between 8.6 and 35 for the interrelation and who first suggested that the TI could be a reliable measurement for the identification of a cam deformity, the interpretation is different, in that we interpreted the TI as a continuous instead of a dichotomous variable. Our results suggest that a greater  $\alpha$ -angle is related to a higher TI. In other words, one could say that with increasing  $\alpha$ -angle measures, a higher cam deformity will be found. Although this is a fairly logical assumption, it has to our knowledge not previously been quantified.

In the group of dichotomous variables, mean age at surgery was significantly higher in case of a positive cross-over sign (pincer-type and mixed-type FAI) in comparison with the pure cam lesion ( $p < 0.05$ ). The mean age at surgery in the pure cam FAI group was 51.8 years compared to 55.1 years in the mixed-type of FAI group. These observations

might suggest that the hips of patients with a pincer mechanism might be relatively protected from developing end-stage OA. Different mechanisms could support this finding. Firstly, we know that cam-type FAI is more destructive than pincer-type FAI and that the process of joint degeneration in the latter is slower (4,11,40). Secondly, the pincer mechanism creates a natural limitation of the range of motion (ROM). In mixed-type FAI, it is possible that the pincer lesion limits the ROM at which possible abutment of the cam lesion with the acetabular cartilage occurs. Finally, pincer-type FAI has been suggested to develop later in life than cam-type of FAI (4,11,38), which explains the higher age at surgery. Although this was a coincidental finding, we believe it is noteworthy. Further studies to confirm or disprove this finding seem necessary in view of its therapeutic relevance.

Meta-analyses and systematic reviews have identified weak to moderate evidence for the influence of previous heavy physical workload on the occurrence of hip OA. Reported odds ratios range from 1.5 to 9.3 when comparing high with light physical occupational workload (21,23). Similarly, weak to moderate evidence for a positive association between hip OA and physical sports activities has been reported (22). Despite the apparent association between hip OA and activity level, we have not been able to demonstrate a significant correlation between physical activity and age at which hip replacement is required for FAI-related OA. Based on radiographic variables, BMI and activity levels alone, we found that it was unrealistic to make any accurate prediction on the natural course of FAI or on the age at which a patient will develop early OA. We can confirm the findings of Bardakos and Villar (3) and of Pollard *et al* (30) that a hip with FAI is not always prone to early end-stage osteoarthritic degeneration, not even in patients with a high level of physical activity. Considering the high prevalence of FAI-related radiographic findings, a final conclusion might be that not every radiographic abnormality requires urgent treatment. Other factors such as genetic and environmental ones might be crucial to the progression of OA (12,20,30,35,36). Further research into the role of each of these factors and on the relationship between multiple

factors is mandatory to fully understand the natural course of OA in FAI.

An important limitation of this study might be the retrospective nature of the Baecke *et al* questionnaire, which may induce inaccuracies due to the delay between actually performing and recording the activity level. However, the questionnaire has been validated and is well documented (2,5,9,15,16,27,33). The same applies to the technique for using questionnaires to evaluate activity and workload (14). Furthermore, although prospective studies on the natural course of FAI are mandatory, it would take several years before end conclusions might be available. Finally, an additional advantage of using the questionnaire is that it is not flawed by instrument-induced alterations of activity patterns (2,5,9,15,16,27,33).

A second limitation of the present study is that radiographic images were used. Radiography continues to be a practical tool to study aberrant bone morphology. It is cheap, fast and does not require specialist radiological interpretation. However it exposes the patient to a small dose of ionizing radiation. In comparison to CT or MRI, radiography has limitations, because FAI is a three-dimensional condition. CT and MRI also allow to assess femoral neck version, which is yet another possible factor involved in FAI (31). Although AP pelvic radiographs are the gold standard for mechanical hip problems, the presence of pelvic tilt or rotational malposition can influence the reliability of measurements performed on these conventional radiographs (8,18,34,39). Nevertheless, the method we used in our study has been recommended as a screening tool (4). It identifies the important underlying bony abnormalities upon which a diagnosis of FAI may be made. A cross-table lateral radiograph in combination with an AP pelvic view has been validated for the assessment of cam deformity (24). The prevalence of the different types of FAI in our study population and the results of the measurements of the different parameters and angles are in accordance with the literature data (1,8,13,38).

A known limitation of the  $\alpha$ -angle measurement on radiographic images, is that it only detects the location of the abnormal bone (13,17), but tells us nothing about the height of the cam deformity. We

tried to obtain this relevant information by using the TI as an additional variable. While Gosvig *et al* (13) originally used it to decide on the presence or absence of a deformity by using a specific cut-off point, we used the absolute values to quantify the height of the cam deformity.

A final limitation refers back to the general model of the development of OA (12,20). As mentioned above, multiple factors are known to play a role and can be segregated in genetic factors, environmental factors and age. A strong argument for the importance of genetic and environmental factors was provided by Takeyama *et al* (36) who reported a 0.6% incidence of FAI-related OA in an Asian population, whereas Stulberg *et al* (35) found abnormal head-neck configurations of the proximal femur in up to 40% of Caucasian patients with idiopathic arthritis. Very recently, Pollard *et al* (30) showed the importance of genetic influences in the initial development of both cam and pincer deformity and they also suggested that these could play a role in disease progression. Further studies are needed to confirm these statements. To incorporate all possible variables in a single model would be an immense challenge. Furthermore, the size of the study population, required for a reliable multivariate regression model including so many parameters, would have to be extremely large.

## CONCLUSION

We found that it is difficult to accurately predict the age at which a patient with FAI will develop early OA. From our findings it appears that a hip with FAI is not always prone to early end-stage osteoarthritic degeneration, not even in patients with a high level of physical activity. The importance of genetic and environmental factors might be underestimated in FAI-related OA. Finally, considering the high prevalence of FAI-related radiographic findings, we conclude that not every radiographic abnormality requires treatment.

## REFERENCES

1. Allen D, Beaulé PE, Ramadan O, Doucette S. Prevalence of associated deformities and hip pain in patients with

- cam-type femoroacetabular impingement. *J Bone Joint Surg* 2009 ; 91-B : 589-594.
2. **Baecke JA, Burema J, Frijters JE.** A short questionnaire for the measurement of habitual physical activity in epidemiological studies. *Am J Clin Nutr* 1982 ; 36 : 936-942.
  3. **Bardakos NV, Villar RN.** Predictors of progression of osteoarthritis in femoroacetabular impingement : a radiological study with a minimum of ten years follow-up. *J Bone Joint Surg* 2009 ; 91-B : 162-169.
  4. **Beck M, Kalhor M, Leunig M, Ganz R.** Hip morphology influences the pattern of damage to the acetabular cartilage : femoroacetabular impingement as a cause of early osteoarthritis of the hip. *J Bone Joint Surg* 2005 ; 87-B : 1012-1018.
  5. **Clarke PE, Rousham EK, Gross H, Halligan AW, Bosio P.** Activity patterns and time allocation during pregnancy : a longitudinal study of British women. *Ann Hum Biol* 2005 ; 32 : 247-258.
  6. **Dihlmann W, Frik W.** [Plaque marks on the hip joint.] (in German). *Fortschr Roentgenstr* 1971 ; 114 : 297-304.
  7. **Durnin JVGA, Passmore R.** *Energy, Work and Leisure.* Heinemann Educational Books Ltd, London, 1967, pp 1-166.
  8. **Ecker TM, Tannast M, Puls M, Siebenrock KA, Murphy SB.** Pathomorphologic alterations predict presence or absence of hip osteoarthritis. *Clin Orthop Relat Res* 2007 ; 465 : 46-52.
  9. **Florindo AA, Latorre MR, Santos EC et al.** Validity and reliability of the Baecke questionnaire for the evaluation of habitual physical activity among people living with HIV/AIDS. *Cad Saude Publica* 2006 ; 22 : 535-541.
  10. **Fritz AT, Reddy D, Meehan JP, Jamali AA.** Femoral neck exostosis, a manifestation of cam/pincer combined femoroacetabular impingement. *Arthroscopy* 2010 ; 26 : 121-127.
  11. **Ganz R, Leunig M, Leunig-Ganz K, Harris WH.** The etiology of osteoarthritis of the hip : an integrated mechanical concept. *Clin Orthop Relat Res* 2008 ; 466 : 264-272.
  12. **Goldring MB, Goldring SR.** Osteoarthritis. *J Cell Physiol* 2007 ; 213 : 626-634.
  13. **Gosvig KK, Jacobsen S, Palm H, Sonne-Holm S, Magnusson E.** A new radiological index for assessing asphericity of the femoral head in cam impingement. *J Bone Joint Surg* 2007 ; 89-B : 1309-1316.
  14. **Gosvig KK, Jacobsen S, Sonne-Holm S, Gebuhr P.** The prevalence of cam-type deformity of the hip joint : a survey of 4151 subjects of the Copenhagen Osteoarthritis Study. *Acta Radiol* 2008 ; 49 : 436-441.
  15. **Hertogh EM, Monninkhof EM, Schouten EG, Peeters PH, Schuit AJ.** Validity of the Modified Baecke Questionnaire : comparison with energy expenditure according to the doubly labeled water method. *Int J Behav Nutr Phys Act* 2008 ; 5 : 30.
  16. **Jakobsen LH, Rask IK, Kondrup J.** Validation of hand-grip strength and endurance as a measure of physical function and quality of life in healthy subjects and patients. *Nutrition* 2010 ; 26 : 542-550.
  17. **Johnston TL, Schenker ML, Briggs KK, Philippon MJ.** Relationship between offset angle alpha and hip chondral injury in femoroacetabular impingement. *Arthroscopy* 2008 ; 24 : 669-675.
  18. **Kalberer F, Sierra RJ, Madan SS, Ganz R, Leunig M.** Ischial spine projection into the pelvis : a new sign for acetabular retroversion. *Clin Orthop Relat Res* 2008 ; 466 : 677-683.
  19. **Leunig M, Beaulé PE, Ganz R.** The concept of femoroacetabular impingement : current status and future perspectives. *Clin Orthop Relat Res* 2009 ; 467 : 616-622.
  20. **Li Y, Xu L, Olsen BR.** Lessons from genetic forms of osteoarthritis for the pathogenesis of the disease. *Osteoarthritis Cartilage* 2007 ; 15 : 1101-1105.
  21. **Lievensen A, Bierma-Zeinstra S, Verhagen A, Verhaar J, Koes B.** Influence of work on the development of osteoarthritis of the hip : a systematic review. *J Rheumatol* 2001 ; 28 : 2520-2528.
  22. **Lievensen AM, Bierma-Zeinstra SM, Verhagen AP et al.** Influence of sporting activities on the development of osteoarthritis of the hip : a systematic review. *Arthritis Rheum* 2003 ; 49 : 228-236.
  23. **Maetzel A, Makela M, Hawker G, Bombardier C.** Osteoarthritis of the hip and knee and mechanical occupational exposure--a systematic overview of the evidence. *J Rheumatol* 1997 ; 24 : 1599-1607.
  24. **Meyer DC, Beck M, Ellis T, Ganz E, Leunig M.** Comparison of six radiographic projections to assess femoral head/neck asphericity. *Clin Orthop Relat Res* 2006 ; 445 : 181-185.
  25. **Netherlands Nutrition Table.** 's-Gravenhage : Netherlands Nutrition Council 2009 (Dutch).
  26. **Notzli HP, Wyss TF, Stoecklin CH et al.** The contour of the femoral head-neck junction as a predictor for the risk of anterior impingement. *J Bone Joint Surg* 2002 ; 84-B : 556-560.
  27. **Philippaerts RM, Lefevre J.** Reliability and validity of three physical activity questionnaires in Flemish males. *Am J Epidemiol* 1998 ; 147 : 982-990.
  28. **Philippaerts RM, Westerterp KR, Lefevre J.** Doubly labelled water validation of three physical activity questionnaires. *Int J Sports Med* 1999 ; 20 : 284-289.
  29. **Pitt MJ, Graham AR, Shipman JH, Birkby W.** Herniation pit of the femoral neck. *AJR Am J Roentgenol* 1982 ; 138 : 1115-1121.
  30. **Pollard TC, Villar RN, Norton MR et al.** Genetic influences in the aetiology of femoroacetabular impingement : a sibling study. *J Bone Joint Surg* 2010 ; 92-B : 209-216.
  31. **Pollard TC, Villar RN, Norton MR et al.** Femoroacetabular impingement and classification of the cam deformity : the reference interval in normal hips. *Acta Orthop* 2010 ; 81 : 134-141.



32. **Reynolds D, Lucas J, Klaue K.** Retroversion of the acetabulum. A cause of hip pain. *J Bone Joint Surg* 1999 ; 81-B : 281-288.
33. **Rousham EK, Clarke PE, Gross H.** Significant changes in physical activity among pregnant women in the UK as assessed by accelerometry and self-reported activity. *Eur J Clin Nutr* 2006 ; 60 : 393-400.
34. **Siebenrock KA, Kalbermatten DF, Ganz R.** Effect of pelvic tilt on acetabular retroversion : a study of pelvis from cadavers. *Clin Orthop Relat Res* 2003 ; 407 : 241-248.
35. **Stulberg SD.** Unrecognized childhood hip disease : a major cause of idiopathic osteoarthritis of the hip. In : Cordell LD HWRPMGe, ed. *The Hip : Proceedings of the Third Open Scientific Meeting of the Hip Society*. St Louis : MO : CV Mosby ; 1975 : 212-228.
36. **Takeyama A, Naito M, Shiramizu K, Kiyama T.** Prevalence of femoroacetabular impingement in Asian patients with osteoarthritis of the hip. *Int Orthop* 2009 ; 33 : 1229-1232.
37. **Tannast M, Goricki D, Beck M, Murphy SB, Siebenrock KA.** Hip damage occurs at the zone of femoroacetabular impingement. *Clin Orthop Relat Res* 2008 ; 466 : 273-280.
38. **Tannast M, Siebenrock KA, Anderson SE.** Femoroacetabular impingement : radiographic diagnosis – what the radiologist should know. *Radiologia* 2008 ; 50 : 271-284.
39. **Tannast M, Zheng G, Anderegg C et al.** Tilt and rotation correction of acetabular version on pelvic radiographs. *Clin Orthop Relat Res* 2005 ; 438 : 182-190.
40. **Tanzer M, Noiseux N.** Osseous abnormalities and early osteoarthritis : the role of hip impingement. *Clin Orthop Relat Res* 2004 ; 429 : 170-177.
41. **Tonnis D, Heinecke A.** Acetabular and femoral anteversion : relationship with osteoarthritis of the hip. *J Bone Joint Surg* 1999 ; 81-A : 1747-1770.
42. **Wenger DE, Kendell KR, Miner MR, Trousdale RT.** Acetabular labral tears rarely occur in the absence of bony abnormalities. *Clin Orthop Relat Res* 2004 ; 426 : 145-150.
43. **Wiberg G.** The anatomy and roentgenographic appearance of a normal hip joint. *Acta Chirurg Scand* 1939 ; 83 : 7-38.