



## Surgical stabilisation of the proximal tibiofibular joint using temporary fixation A technical note

Michel P. J. VAN DEN BEKEROM, Adam WEIR, Rudolf E. VAN DER FLIER

*From the Medical Centre Haaglanden, Antoniushove Hospital, Leidschendam, The Netherlands*

**Proximal tibiofibular instability is a symptomatic hypermobility of this joint possibly associated with subluxation. It is a rare condition both in clinical practice and in literature.**

**The treatment of choice for proximal tibiofibular instability remains conservative, using a brace 1 cm underneath the head of the fibula. If no improvement is noted after six months of conservative treatment, surgical intervention can be considered : there are several options, such as resection of the head of the fibula, permanent arthrodesis of the proximal tibiofibular joint, reconstruction using either the tendon of the biceps femoris or a portion of the iliotibial tract, or temporary (three to six months) fixation using a screw together with release of the peroneal nerve.**

---

### INTRODUCTION

The term proximal tibiofibular instability indicates symptomatic hypermobility of this joint, associated with subluxation and sometimes even dislocation. It is a rare condition both in clinical practice and in the literature. Some authors suggest that this condition is more prevalent than previously thought but that it is often missed (9, 14).

The diagnosis of instability of the proximal tibiofibular joint is usually based on the history and confirmed during physical examination : hypermobility can be reproduced with manual pressure. Radiology can help in establishing the diagnosis.

Anatomy, clinical presentation, physical examination and direction of instability or luxation have been dealt with extensively and will not be discussed here (9, 10, 13). The main purpose of this article is to describe a simple surgical technique, which offers satisfactory results.

### TREATMENT OF INSTABILITY OF THE PROXIMAL TIBIOFIBULAR JOINT

The treatment of choice remains non-surgical. A supportive strap placed 1 cm below the fibular head can offer relief in many cases. Care should be taken not to apply the strap too tightly or for too long, as this could precipitate a peroneal nerve palsy. The strap should be worn during activities that cause the symptoms (14, 16, 17).

The strap can be combined with strengthening exercises.

---

■ Michel P. J. van den Bekerom, MD, Registrar in Orthopaedic Surgery.

■ Adam Weir, MD, Registrar in Sports Medicine.

■ Rudolf E. van der Flier, MD, Orthopaedic surgeon.

Correspondence : Rudolf van der Flier, Orthopaedic surgeon. Medical Centre Haaglanden, Antoniushove Hospital, Burgemeester Banninglaan 1, 2260 AK Leidschendam, The Netherlands. E-mail : rorthoflier@hotmail.com.

© 2004, Acta Orthopædica Belgica.

---

1. Strengthening of lateral and rotational stability and coordination on a balancing disc or a trampoline.
2. Stretching exercises for m. biceps femoris, m. soleus and m. gastrocnemius.
3. Strengthening exercises of the peroneal muscles with a dynaband. The affected foot is moved in eversion against the resistance of the band.

It is important to avoid activities involving hyperflexion of the knee (6, 14).

If six months of non-surgical treatment do not result in improvement, then a surgical treatment can be considered. The different possibilities are : resection of the fibular head, arthrodesis of the proximal tibiofibular joint, reconstruction of the proximal tibiofibular joint and temporary fixation of the head of the fibula.

### Resection of the fibular head

Resection of the head and neck of the fibula was the operative treatment of choice in Ogden's studies. The fibular styloid and the lateral collateral ligament should be preserved (10, 17). Injury to the peroneal nerve has been described with this procedure (2, 4, 7). If scar tissue is seen around the peroneal nerve, neurolysis should be performed (10). Resection of the fibular head may cause lateral and posterolateral instability of the knee and is therefore not selected in athletes (5, 9, 11, 13). There is also a risk of developing ankle pain (3, 6). The procedure should not be used in children or adolescents because of the associated risk of damage to the growth plate (5). It is probably best indicated in the presence of chronic fibular nerve irritation due to the fibular head dislocation (13).

### Arthrodesis of the proximal tibiofibular joint

An arthrodesis can be performed with or without osteotomy of the fibula. After dissection and protection of the peroneal nerve, the articular cartilage is removed to bleeding subchondral bone. The joint is then fixed in the reduced position with screws. This procedure requires immobilisation of the leg and delayed weight bearing (16). Arthrodesis of the

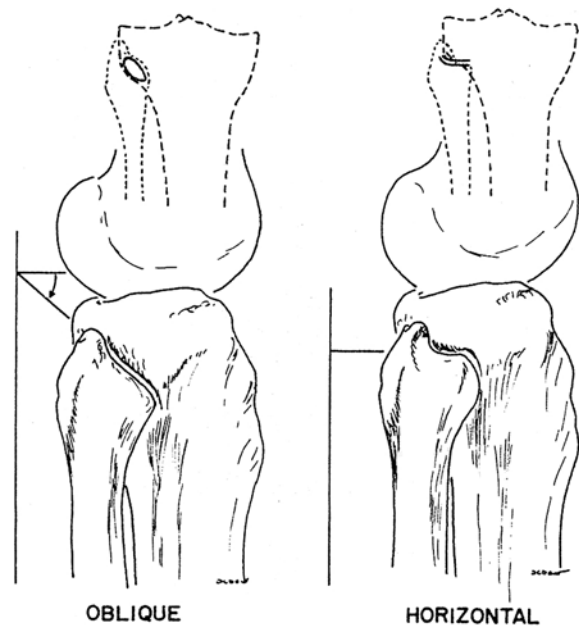


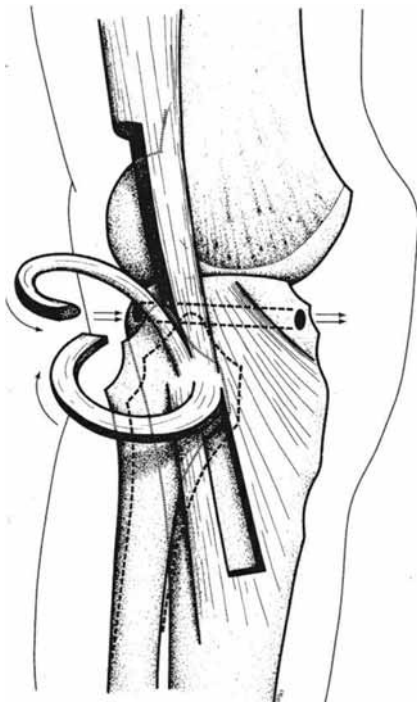
Fig. 1. — Oblique and horizontal type of the proximal tibiofibular joint with the horizontal and oblique proximal tibiofibular joint (reprinted with permission from Ogden JA) (11).

proximal tibiofibular joint causes increased rotational forces in the ankle and often leads to pain and instability of the ankle joint (9, 11, 18). For this reason the operation is contraindicated in children and in athletes (13). The lag screws may break or become loose (16). Some authors recommend a simultaneous osteotomy at the junction of the proximal and the middle third of the fibula shaft and a 1.5-cm resection to prevent overloading the fibula and the arthrodesed joint (11).

### Reconstruction of the proximal tibiofibular joint

Techniques using a portion of the biceps femoris tendon or iliotibial band have been described (1, 4, 19).

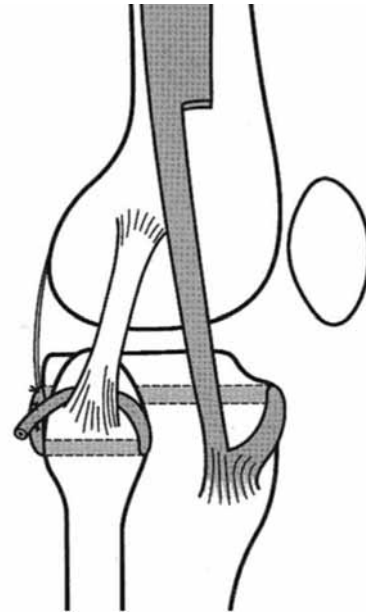
The biceps femoris tendon is divided and a strip of its posterior half is used, leaving the attachment on the head of the fibula intact (5) (fig 2). A strip of fascia from the anterolateral compartment of the leg can be used additionally for augmentation (13). Giachimo drills a hole in the tibia from posterior to



**Fig. 2.** — Reconstruction with the m. biceps femoris tendon (reprinted with permission from Giachino AA) (5).

anterior and the tendinous and ligamentous strips are wrapped around the head of the fibula while the joint is held in a reduced position. The ligaments are then passed through the tibial hole from posterior to anterior and secured to the anterior fascia or the graft is fixed in the tibial tunnel with an interference screw. The knee has to be immobilised for six weeks and progressive weight bearing is then encouraged. Miettinen *et al* (8) drill a transverse hole in the proximal tibia from lateral to medial, starting at the anterior border of the fibular head. The graft is pulled through and fixed in the tibial tunnel with an interference screw.

Shapiro *et al* described a technique to stabilise the joint using a 20 × 2 cm strip of the iliotibial band (15). The distal attachment to Gerdy's tubercle is preserved and the band is passed through a tibial tunnel from anterior to posterior and then passed through the posterior capsule and arcuate complex, and finally through a tunnel in the fibula head from posterior to anterior. It is then routed deep to the lateral collateral ligament in a posterior direction,



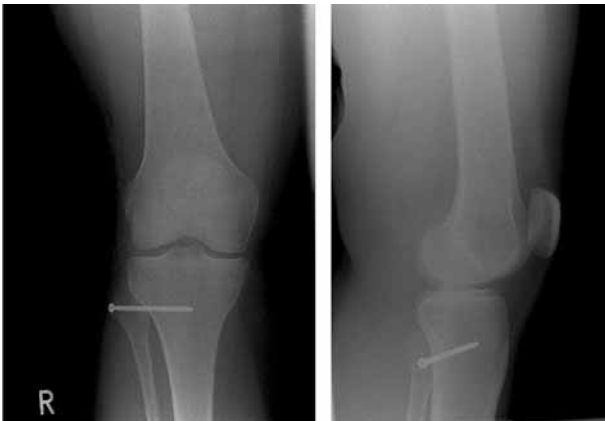**Fig. 3** — Reconstruction with the iliotibial band (reprinted with permission from Shapiro GS, Fanton GS, Dillingham MF) (15).

tightened and sutured to itself and the posterior capsule, with the joint in a reduced position (fig 3).

#### Temporary fixation of the head of the fibula

Parkes *et al* (12) believe that when open reduction and stabilisation should be necessary, temporary stabilisation of the joint with two unthreaded Kirschner wires should be carried out, as well as repair of the torn joint capsule and ligaments. The wires are removed under local anaesthesia after six weeks. The smooth wires are simpler to remove than threaded ones and will not migrate if removed before weight bearing is allowed. If degenerative changes have occurred in the joint, resection of the fibular head would seem preferable to arthrodesis since it is easier technically and less likely to adversely affect the knee or ankle.

Post-operatively a short leg cast with the ankle in neutral position should be applied for six weeks to minimize motion at the superior joint. The cast and wires can both be removed at the same time.



*Fig. 4a, b.* — Anterior and lateral X-ray view of temporary fibular head transfixation.

In our centre we use a technique of temporary fixation of the fibula head combined with release of the common peroneal nerve.

A slightly curved incision from the posterior border of the iliotibial band proximally to the head of the fibula is made. The common peroneal nerve is identified and released and gently retracted proximally underneath the muscle to protect it from injury. The head of the fibula is approached ventrally and the capsule is loosened subperiosteally both ventrally and dorsally taking care to avoid the common peroneal nerve. The ankle is then dorsiflexed and the head of the fibula slightly externally rotated and reduced into the most stable position. Entering the posterior aspect of the fibula head, an anteromedially directed hole is drilled into the tibia. A non-tapped cortical screw is used to fix the fibula head in this stable reduced position (fig 4a, b). The capsule and skin are closed in layers and a pressure bandage is applied. We prefer not to immobilise the knee after the procedure.

The patients are allowed to bear weight immediately after the operation although the knee may not be flexed more than 90° for the first two weeks to allow good healing. Postoperative radiographs are obtained, but we do not use fluoroscopic guidance during the operation. The screw is removed after three to six months.

## RESULTS

We have treated 8 patients using this technique. The operation resulted in alleviation of pain in seven of the eight patients. In the eighth patient a resection osteotomy of the fibula at the junction of the proximal and middle third was performed, which gave relief of the symptoms.

## Complications

Until now there have been no injuries to the common peroneal nerve in our centre but this remains a possible risk of this procedure. The screw has broken before its planned removal in two patients. One of these patients was the patient who underwent the osteotomy due to lack of improvement of the symptoms. The other patient had relief of his symptoms despite the broken screw. In one case the scar was very broad and was surgically corrected by a plastic surgeon at the request of the patient.

## CONCLUSION

Instability of the proximal tibiofibular joint is an uncommon cause of lateral knee pain. Some authors suggest that it is often missed due to lack of awareness about this condition. It can be identified with a good history and physical examination. Non-surgical therapy with modification of activity, supportive straps and a knee strengthening program usually alleviates symptoms. If non-surgical therapy is unsuccessful, surgery can be considered. Resection of the fibula head or arthrodesis is not recommended in athletes or adolescents because of the risk of developing ankle pain or knee instability. Techniques for reconstruction have been described using the biceps femoris tendon or the iliotibial band. These techniques seem to offer good results although the operations require fairly large incisions and extensive soft tissue dissection. They also require at least six weeks of postoperative immobilisation.

In our centre, we prefer to use a temporary fixation technique using one cancellous screw which is removed between three and six months after the

operation. We do not denude the joint surfaces and the technique does not require immobilisation. This procedure has resulted in alleviation of symptoms in seven of eight patients, although the screw broke in two cases.

Although the numbers are small and follow-up is fairly short, this technique seems to offer good results and warrants further assessment.

## REFERENCES

1. **Cazeneuve JF, Bracq H, Meeseman M.** Weinert and Giachino ligament arthroplasty for the surgical treatment of chronic superior tibiofibular joint instability. *Knee Surg Sports Traumatol Arthroscopy* 1997 ; 5 : 36-37.
2. **Dennis JB, Ruledge BA.** Bilateral recurrent dislocations of the superior tibio-fibular joint with peroneal-nerve palsy : A case summary. *J Bone Joint Surg* 1958 ; 40-A : 1146-1148.
3. **Draganich LF, Nicholas RW, Schuster JK et al.** The effects of resection of the proximal part of the fibula on stability of the knee and on gait. *J Bone Joint Surg* 1991 ; 73-A : 575-583.
4. **Falkenberg P, Nygaard H.** Isolated anterior dislocation of the proximal tibio-fibular joint. *J Bone Joint Surg* 1983 ; 65-A : 310-311.
5. **Giachino AA.** Recurrent dislocations of the proximal tibiofibular joint : Report of two cases. *J Bone Joint Surg* 1986 ; 68-A : 1104-1106.
6. **Halbrecht JL, Jackson DW.** Recurrent dislocation of the proximal tibiofibular joint. *Orthop Rev* 1991 ; 20 : 957-960.
7. **Keogh P, Masterson E, Murphy B et al.** The role of radiography and computed tomography in the diagnosis of acute dislocation of the proximal tibiofibular joint. *Br J Radiol* 1993 ; 66 : 108-111.
8. **Miettinen H, Kettunen J, Vaatainen U.** Dislocation of the proximal tibiofibular joint. A new method for fixation. *Arch Orthop Trauma Surg* 1999 ; 119 : 358-359.
9. **Ogden JA.** Subluxation of the proximal tibiofibular joint. *Clin Orthop* 1974 ; 101 : 192-197.
10. **Ogden JA.** The anatomy and function of the proximal tibiofibular joint. *Clin Orthop* 1974 ; 101 : 186-191.
11. **Ogden JA.** Subluxation and dislocation of the proximal tibiofibular joint. *J Bone Joint Surg* 1974 ; 56-A : 145-154.
12. **Parkes JC II, Zelko RR.** Isolated acute dislocation of the proximal tibiofibular joint : Case report. *J Bone Joint Surg* 1973 ; 55-A : 177-183.
13. **Sekiya JK, Kuhn JE.** Instability of the proximal tibio-fibular joint. *J Am Acad Orthop Surg* 2003 ; 11 : 120-128.
14. **Semonian RH, Denlinger PM, Duggan RJ.** Proximal tibiofibular subluxation relationship to lateral knee pain : A review of proximal tibiofibular joint pathologies. *J Orthop Sports Phys Ther* 1995 ; 21 : 248-257.
15. **Shapiro GS, Fanton GS, Dillingham MF.** Reconstruction for recurrent dislocation of the proximal tibiofibular joint : a new technique. *Orthop Rev* 1993 ; 22 : 1229-1232.
16. **Sijbrandij S.** Instability of the proximal tibiofibular joint. *Acta Orthop Scand* 1978 ; 49 : 621-626.
17. **Turco VJ, Spinella AJ.** Anterolateral dislocation of the head of the fibula in sports. *Am J Sports Med* 1985 ; 13 : 209-215.
18. **Weinert CR, McMaster JH, Ferguson RJ.** Dynamic function of the human fibula. *Am J Anat* 1973 ; 138 : 145-149.
19. **Weinert CR, Raczka R.** Recurrent dislocation of the superior tibiofibular joint : Surgical stabilisation by ligament reconstruction. *J Bone Joint Surg* 1986 ; 68-A : 126-128.