



Assessment of percutaneous V osteotomy of the calcaneus with Ilizarov application for correction of complex foot deformities

Hani EL-MOWAFI

From Mansoura University Hospital, Egypt

Complex foot deformity can be described as a foot with multiplanar abnormalities with or without shortening of the foot. Conventional surgical treatment may not be able to correct these deformities. In this study we evaluate the results of percutaneous V osteotomy of the calcaneus with an Ilizarov external fixator for treatment of complex foot deformity.

Twenty feet with a complex deformity were treated by the Ilizarov method in 15 patients. The aetiological factors were neglected or relapsed clubfoot (13 patients) and poliomyelitis (2 patients). All patients underwent percutaneous V osteotomy of the calcaneus and gradual correction of the deformity using Ilizarov's method. The mean duration of fixator application was 9.5 months (range, 6-13 months). The mean follow-up period was 1.8 years (range, 1 to 3 years). At the time of fixator removal, a plantigrade foot was achieved in 18 cases ; gait was improved in all patients. There was residual varus deformity in two patients. A pin-tract infection was observed in all patients. No recurrence of the deformity occurred. The V osteotomy offers the most options for correction of complex foot deformities. Percutaneous technique is particularly useful for the complex foot deformity that has poor skin coverage, with poor blood supply. Gradual correction with the Ilizarov method yields good results for complex foot deformities.

INTRODUCTION

Complex foot deformity is one of the most challenging conditions in orthopaedic surgery. There

are many causes for such deformity, such as trauma, neglected or relapsed clubfoot, poliomyelitis, osteomyelitis, burn contracture, and neuromuscular disease. The goal of any complex foot surgery is to obtain a cosmetically acceptable, functional, painless, and plantigrade foot (14). For cases with unusually severe deformities, or an untreated or relapsed clubfoot or a severe post-burn contracture, conventional reconstructive foot procedures are not satisfactory for correction (5). Simple deformities often can be handled with simple techniques but more complex problems often require more elaborate solutions (15). All these cases have poor soft tissue coverage, shortening of the foot and a neurovascular disorder. A complex foot deformity can be described as a foot with multiplanar abnormalities with or without shortening of the foot (7).

Many authors consider the Ilizarov method as the best choice for the correction of complex foot deformities because it enables correction in all three orthogonal planes. It causes minimal surgical morbidity without shortening of the foot and allows

■ Hani El-Mowafi, MD, Assistant Professor.

Orthopaedic Department, Mansoura University Hospital, Mansoura, Egypt.

Correspondence : Hani El-Mowafi, Mansoura University Hospital, Faculty of Medicine, 35516 Mansoura, Egypt.

E-mail : hanielmowafi@yahoo.com.

© 2004, Acta Orthopædica Belgica.

the surgeon to tune the rate and direction of the correction (7, 11, 12). Different methods of osteotomy were described, such as supramalleolar osteotomy, U osteotomy of the calcaneus, or midfoot osteotomy. These osteotomies can correct the foot deformity in one plane such as equinus, calcaneus, valgus, or varus (5). The V osteotomy offers the most options for correction of complex foot deformity in different planes. The V osteotomy is actually two osteotomies, as it consists of two limbs, a posterior limb and an anterior limb. This osteotomy can divide the calcaneus into three segments (anterior, posterior and middle). The posterior segment can move independently of the rest of the foot to correct hindfoot varus, valgus, equinus and calcaneus deformities. It may also be used to lengthen the hindfoot. The anterior segment can be used for corrections of forefoot equinus, supination, pronation, adduction and abduction (5).

The purpose of this study was to evaluate the results of percutaneous V osteotomy of the calcaneus with the Ilizarov external fixator, for treatment of complex foot deformity.

PATIENTS AND METHODS

Twenty feet with complex deformity were treated in 15 patients with percutaneous V osteotomy of the calcaneus and gradual correction by the Ilizarov method. There were 8 males and 7 females with an average age of 15.7 years (range : 11 to 40). The aetiologic factors were neglected or relapsed clubfoot (13 patients) and poliomyelitis (2 patients). The preoperative assessment was based on clinical evaluation and imaging studies. The clinical evaluation consisted of range of motion and neurovascular assessment. Imaging studies included plain radiographs, computed tomography (CT), 3D reconstruction CT, photography and Doppler ultrasonography. Percutaneous V osteotomy was carried out in all patients.

Operative technique :

A small transverse incision (2-3 cm) was made at the inferior lateral border of the calcaneus. Under the image intensifier, the midportion of the plantar lateral surface of the calcaneus was identified. Using a small osteotome, the posterior osteotomy was started at this point and directed superiorly, posteriorly and distally to

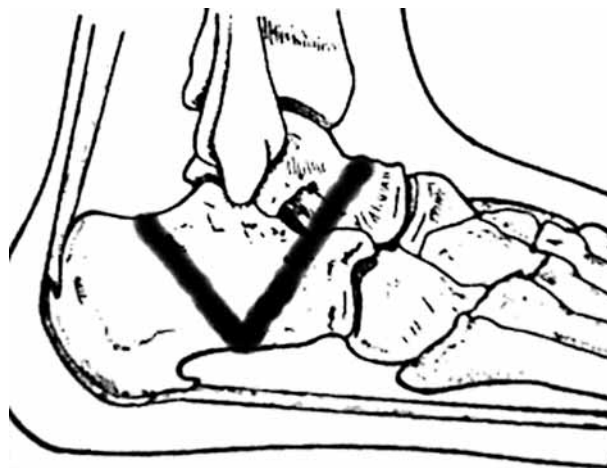


Fig. 1. — Schematic drawing of osteotomy crossing the subtalar joint and the neck of the talus.

the dorsum of the calcaneal tuberosity. The anterior osteotomy was started from the same point on the inferior portion of the plantar surface of the calcaneus directed superiorly and anteriorly and distally across the anterior and middle subtalar joint and across the neck of the talus (fig 1). If there was dislocation of the head of the talus, there was no need to proceed across the subtalar joint and neck of the talus (fig 2). Two wires could be inserted, one in the anterior segment with the other in the posterior segment before application of the Ilizarov frame. With two wires we could assess the osteotomy under the image intensifier. The frame was constructed and could mimic the deformity. The frame consisted of 3 parts, the part on the leg, the heel and the forefoot. The third wire was inserted into the central segment and could be fixed with the leg part of the frame. To prevent toe contracture, K-wires were inserted into all toes, and fixed to the forefoot part of the frame. Soft tissue release was combined with the V osteotomy in relapsed cases. Correction was started on the second postoperative day to prevent premature consolidation. In order to prevent crushing of the cartilage of the talar dome, the ankle joint and the heel could be distracted while pulling up the forefoot. The rate of medial distraction was 1 mm/day, with lateral distraction at a much slower rate of 0.25 mm/day. The articular cartilage of the midfoot joints was thus protected from compressive forces. The fixator duration depended on the deformity types. After correction of the deformity, the frame was removed after a period equal to one and a half times the period of correction. Immediately on removal of the apparatus, a

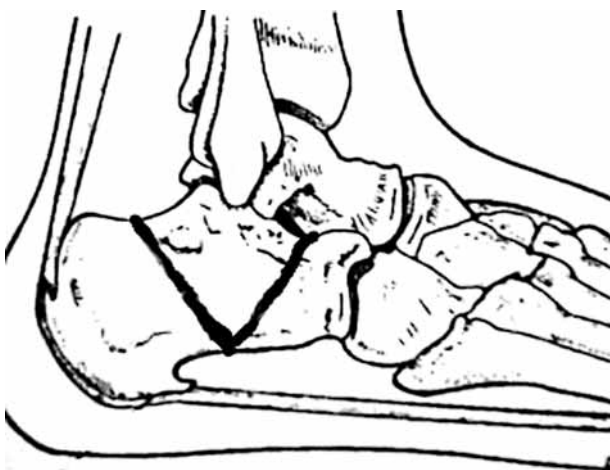


Fig. 2. — Schematic drawing of osteotomy end at the subtalar joint.

long-term orthosis was used to maintain the correction. Postoperatively, the patient was evaluated clinically and radiologically.

RESULTS

The mean follow-up period was 1.8 years (range : 1 to 4 years). The correction period ranged from 2 months to 6 months. The mean duration of fixator application was 9.5 months (range : 5 to 13). At the time of fixator removal, a plantigrade foot was achieved in 18 cases. Mild residual varus and equinus deformities were present in two patients. Average ankle dorsiflexion and plantar flexion were 10° (range : 7 to 12) and 25° (range : 20 to 28), respectively. At the early follow-up visit there was pain during walking and standing. In the last follow-up, there was no pain during activity. Compared to the preoperative status, gait was markedly improved. Radiographs showed that the talocalcaneal angle in the lateral plane ranged from 22° to 28° (mean 24.3°) (fig 3, 4).

Complications were incomplete osteotomy in 3 feet, pin-tract infection in all cases, pin loosening in 9 patients and mild residual varus deformity in 2 patients. Re-osteotomy was performed in 3 patients. Conservative treatment was done for pin-tract infection except for 3 patients who need-

ed replacement of the pin. Pin reinsertion was performed for 9 patients who had pin loosening.

DISCUSSION

Complex deformities of the foot and ankle remain a difficult problem even for the most experienced surgeon (15). Many techniques are available to provide correction. All of these procedures have the potential for a range of complications. The clinician should perform the least invasive procedure that decreases pain and improves function (10). When poor soft tissues are present, conventional open osteotomy is not possible. Scar tissue from previous surgery can complicate further surgical correction (13).

The Ilizarov technique has been suggested as an option for correction of complex foot deformity (3, 4). It is less invasive and allows for simultaneous correction of all components of the deformity without resection of bone or shortening of the foot. Soft tissue viability and function can be assessed directly and the rate of correction can be adjusted accordingly (2). There are two different methods for correction of foot deformities by the Ilizarov technique, with and without an osteotomy. In 2002, Hosny (6) reported that 23 foot deformities were treated by non-osteotomy technique with the Ilizarov application. The age of the patients ranged from 2.6 years to 49.0 years. All his patients had a plantigrade foot. Bradish *et al* (1) reported on 17 relapsed feet treated with the Ilizarov method with gradual distraction and realignment. There were excellent or good results in 13 feet. Lejman *et al* (9) reported on 34 recurrent clubfeet treated with the Ilizarov technique without additional surgery. The age of the patients ranged from 2.5 years to 14 years. Twenty-six results were rated good, 4 fair and 4 poor. On the other hand, many authors recommended a non-osteotomy technique for patients who had a congruous joint with no significant fixed bony deformities and for children younger than 8 years of age, as the incidence of the deformity and recurrence was high in such cases (5, 7). Herzenberg *et al* (5) claim that recurrence of deformity is rare in the osteotomy technique, while it is common in the non-osteotomy technique.

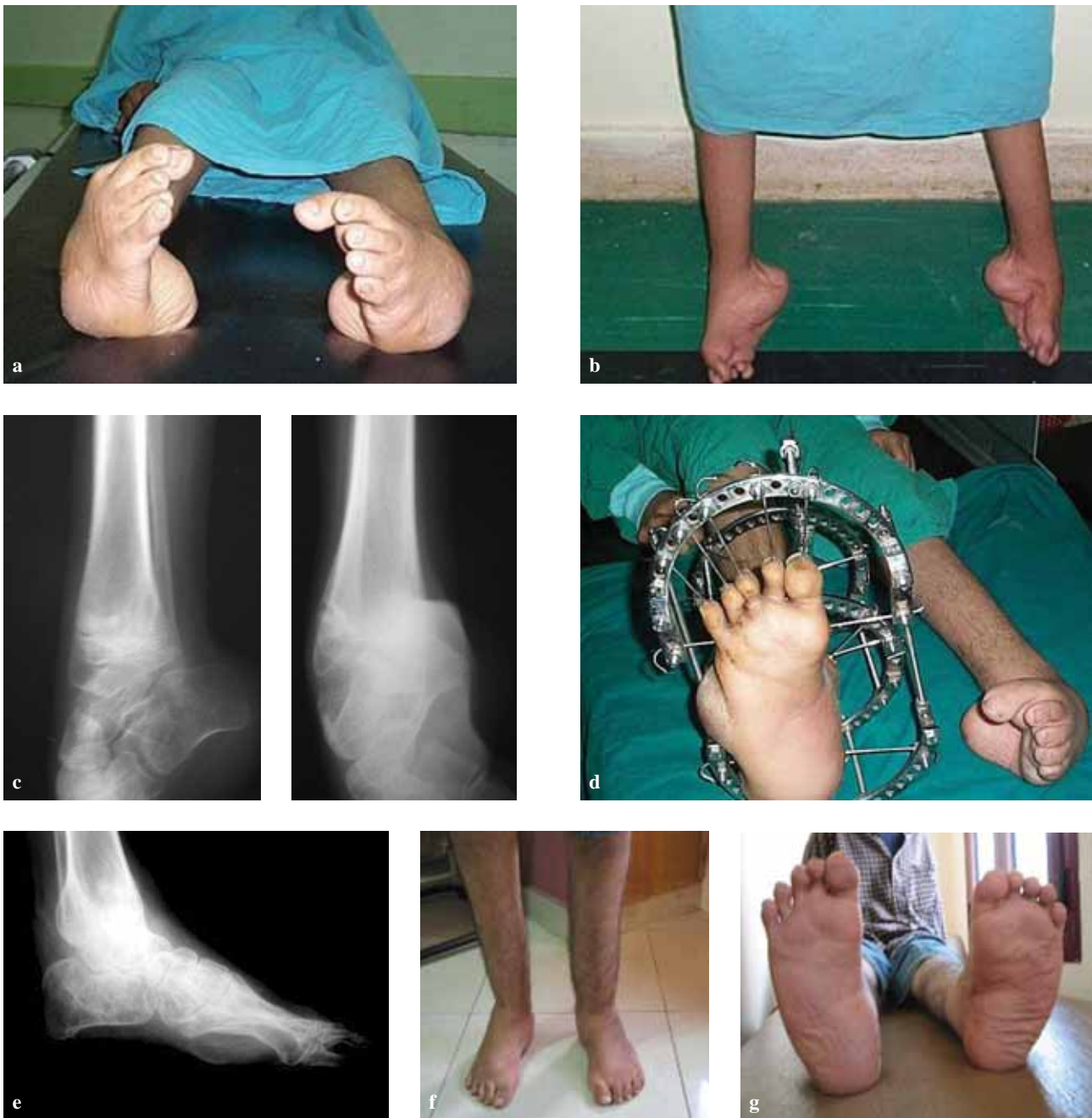

Fig. 3. — a and b) Preoperative appearance of the patient, c) Preoperative radiograph, d) Right side in the frame, e) Postoperative radiograph, f and g) After correction of both feet.

In 1993, Paley (12) reported on 25 complex foot deformities treated by Ilizarov distraction osteotomies. He used more than one type of osteotomy, such as supramalleolar, U, V, posterior calcaneal, talocalcaneal neck, midfoot, and

metatarsal osteotomies. Satisfactory results were achieved in 22 feet and unsatisfactory outcomes in three. Kocaoglu *et al* (7) reported on 14 feet treated with different methods of osteotomies ; gait was improved in all patients. Herzenberg *et al* (5) report-

ed that in cases with calcaneal deformity with a normal relationship of the forefoot to the hindfoot, supramalleolar osteotomy can correct this deformity. They indicated that U osteotomy is technically demanding and certain structures are at risk. Kucukkaya *et al* (8) reported that 9 feet with neurologic foot deformities were treated by V osteotomy and the Ilizarov method. A painless and plantigrade foot was obtained in 8 feet. There were no major complications. In this study, there was pain in 10 patients in early follow-up, and in the last follow-up there was no pain. This can be explained if the deformity was severe and the patient could not walk on his feet. After correction, there was abnormal feeling during standing and walking. Also there was marked osteoporosis in the foot. After removal of the frame, the patients underwent a rehabilitation program.

Kocaoglu *et al* (7) and Paley (12) reported that toe contracture and metatarsophalangeal joint subluxation were the common complications in their study. In this study, there were no toe contractures or metatarsophalangeal joint subluxations. This is explained by the insertion of K-wires in all toes to prevent toe contracture during application of the frame. Percutaneous calcaneal V osteotomy was particularly useful for those patients who had poor skin coverage, and it decreased the incidence of the neurovascular injury. Paley (12) reported the development of acute tarsal tunnel syndrome in two cases treated by U or V osteotomies. Kocaoglu *et al* (7) did not observe neurovascular injuries in their study. Herzenberg *et al* (5) reported that V osteotomy can correct the complex foot deformity even if the hindfoot and forefoot are not in a normal relationship.

CONCLUSION

Complex foot deformities of any cause can be treated with percutaneous calcaneal V osteotomy with the Ilizarov gradual correction method. The percutaneous technique is particularly useful for complex foot deformities with poor skin coverage and poor blood supply. V osteotomy allows the sur-

geon to correct the severe degrees and combination of hindfoot, midfoot and forefoot deformities. The Ilizarov frame helps the surgeon to correct the deformities in three planes.

REFERENCES

1. **Bradish CF, Noor S.** The Ilizarov method in the management of relapsed club foot. *J Bone Joint Surg* 2000 ; 82-B : 387-391.
2. **Choi IH, Yang MS, Chung CY et al.** The treatment of recurrent arthrogryptic club foot in children by the Ilizarov method. *J Bone Joint Surg* 2001 ; 83-B : 731-737.
3. **Desgrippes Y, Souchet P, Bensahel H.** Use of the Ilizarov external fixator in multioperated recurrent clubfoot. *J Pediatr Orthop* 1992 ; 1 : 181-186.
4. **Henrik W, Goran H, Bjorn T.** Correction of persistent clubfoot deformities with the Ilizarov external fixator. *Acta Orthop Scand* 1996 ; 67 : 283-287.
5. **Herzenberg JE, Paley D.** Ilizarov applications in foot and ankle surgery. *Adv Orthop Surg* 1992 ; 16 : 162-174.
6. **Hosny GA.** Correction of foot deformities by the Ilizarov method without corrective osteotomies or soft tissue release. *J Pediatr Orthop* 2002 ; 11-B : 121-128.
7. **Kocaoglu M, Erlap L, Atalar AC, Bilen FE.** Correction of complex foot deformities using the Ilizarov external fixator. *J Foot Ankle Surg* 2002 ; 41 : 30-39.
8. **Kucukkaya M, Kabukuoglu Y, Kuzgun U.** Management of the neuromuscular foot deformity with the Ilizarov method. *Foot Ankle Int* 2002 ; 23 : 135-141.
9. **Lejman T, Sulko J, Kowalczyk B.** Treatment for recurrent clubfoot with the Ilizarov technique. *Chir Narzadow Ruchu Ortop Pol* 1998 ; 63 : 39-45.
10. **Neufeld SK, Myerson MS.** Complications of surgical treatments for adults flatfoot deformities. *Foot Ankle Clin* 2001 ; 6 : 179-191.
11. **Paley D.** Principles of foot deformity corrections. In : Gould JS (ed). *Operative Foot Surgery*, Saunders, Philadelphia, 1994, pp 476-514.
12. **Paley D.** The correction of complex foot deformities using Ilizarov's distraction osteotomies. *Clin Orthop* 1993 ; 11 : 238-240.
13. **Steinwender G, Saraph V, Zwick EB, Uitz C, Linhart W.** Complex foot deformities associated with soft-tissue scarring in children. *J Foot Ankle Surg* 2001 ; 40 : 42-49.
14. **Suresh S, Ahmed A, Sharma VK.** Role of Josh's external stabilisation system fixator in the management of idiopathic clubfoot. *J Orthop Surg* 2003 ; 11 : 194-201.
15. **Thompson DM, Calhoun JH.** Advanced techniques in foot and ankle reconstruction. *Foot Ankle Clin* 2000 ; 5 : 417-442.