

UNICONDYLAR FEMORAL FRACTURES : THERAPEUTIC STRATEGY AND LONG-TERM RESULTS. A REVIEW OF 23 PATIENTS

M. MANFREDINI, A. GILDONE, R. FERRANTE, S. BERNASCONI, L. MASSARI

Unicondylar femoral fractures account for 0.65% of all femoral fractures ; they have not been studied extensively in the orthopedic literature. Usually occurring following sports trauma or traffic accidents, these fractures involve the lateral condyle three times more frequently than the medial condyle. Conservative or surgical treatment has been advocated, depending on the fracture type.

From 1986 to 1999, 19 patients with unicondylar femoral fractures were surgically treated at our institution : there were 15 males and 4 females, aged 36.2 years on average. According to the AO-ASIF classification, there were 7 B1, 6 B2 and 6 B3 fractures. We used Herbert screws in six cases, Barr screws together with cancellous screws in two, cannulated screws in five, cancellous screws alone in four, a compression screw and plate in one and a T-plate in one.

In the same period of time, four patients were treated conservatively with a cast. Sixteen patients treated surgically were evaluated with a mean follow-up of 60 months, using Shatzker and Lambert's criteria : six results were rated as excellent, five good, four fair and one poor, while conservative treatment gave three fair and one poor results.

In conclusion, we think that open reduction and internal fixation are essential in the treatment of such fractures.

Keywords : femoral condyle, fracture, fixation.

Mots-clés : condyle fémoral ; fracture ; ostéosynthèse.

INTRODUCTION

Unicondylar fractures of the femur are characterized by avulsion of one femoral condyle while the other intact condyle remains in continuity with the femoral metaphysis (1). Accounting for only 0.65% of all femoral fractures (5, 7, 10), they have never been reviewed extensively in the orthopedic literature, in particular as a class of fracture. They have almost always been included in the generic group of distal-third femoral fractures (8, 10). Unicondylar femoral fractures represent a diagnostic problem, as they are often overlooked owing to their frequent association with other fractures of the same limb or in other regions. Moreover, they show great anatomical variability, resulting in difficult radiologic evaluation and in a controversial therapeutic approach (8). They occur following direct impact, avulsion or action of shear forces on the knee, generally in sports activities or traffic accidents, particularly dashboard trauma (4, 10, 11, 12, 13). The critical point is represented by the trochlear-condylar groove, located at the junction between the trochlea and the medial and lateral condyles ; starting from this typical site, the fracture line may be frontal, sagittal or oblique in each condyle (1, 10, 13). The lateral condyle is involved three times as often as the medial one (1, 6, 8, 13).

Department of Biomedical Sciences and Advanced Therapies, Orthopedic Institute, Ferrara University, Ferrara, Italy.

Correspondence and reprints : M. Manfredini, Via Pro.le Motta 51, 41030 Rovereto di Novi di Modena (MO) Italy.

The physiological valgus causes an abduction component, which explains the greater frequency of lateral condyle fractures (8). The broader area of the lateral flange of the trochlea, as well as its orientation in an oblique plane, increases the exposure of the lateral condyle (8,12). Various classification systems include those of Egund-Kolmert, Seinsheimer, Neer-Grantham-Shelton and the AO-ASIF system. Such fractures may be managed either conservatively or surgically (1). Conservative treatment consists of a femoral-malleolar cast or a functional cast with the knee in moderate flexion, that may be preceded by skeletal traction (1, 5, 7, 10). Surgical treatment consists of open reduction and stabilization by different techniques, such as condylar plates, cancellous screws, cannulated screws, Herbert screws, Barr screws, or a compression screw and plate (3, 6, 9, 10). Unicondylar fractures are frequently displaced and unstable because of the initial trauma force, the muscle contraction, in particular, the gastrocnemius and popliteus muscles which can rotate and move the condylar fragments (3), and the orientation of the fracture line itself, which creates a sliding plane favoring upward condylar movement (1, 8, 13). Fractures of the lateral and medial condyle tend to heal with a valgus and varus deformity, respectively. In the literature, a 20% incidence of early osteoarthritis in the femoropatellar compartment is observed in cases of malunited fractures. In addition, a significant increase in the incidence of osteoarthritis is seen in the presence of a step-off of over 3 mm on the articular surface (2, 10).

Data from the literature support surgical treatment of almost all unicondylar fractures, owing to their tendency to displace over time (8, 10). Particular attention should be given to the AO-ASIF B3-type fractures, also known as Hoffa fractures, because of their high risk of avascular necrosis (6). Loosening of the fixation can represent a real problem in the presence of osteoporosis, as fragmentation and secondary displacement may occur (8, 10). Surgical stabilization has a higher incidence of failure in patients over 50, where good results depend on the surgeon's skill (2).

We reviewed a series of patients who had undergone surgery for unicondylar fractures to evaluate

relevant short-, middle- and long-term advantages compared to conservative treatment.

PATIENTS AND METHODS

A total of 19 unicondylar fractures of the femur were surgically treated from January 1986 to May 1999 in the Orthopedics department of the Saint Anna Hospital in Ferrara (Italy). There were 15 males and 4 females, with an average age of 36.2 years (range, 17 to 52 years). Seven fractures were classified as B1, 6 as B2 and 6 as B3 according to the AO-ASIF system (fig. 1). The lateral condyle was involved in 13 cases, the medial condyle in 6. Associated lesions were relatively frequent, usually in the same limb : 1 femoral fracture, 1 patellar fracture and 2 anterior cruciate ligament ruptures. Four other patients also presenting with a unicondylar femoral fracture were treated conservatively. Three fractures in this subgroup involved the lateral condyle and one the medial condyle. Two multiply-injured patients, aged 35 and 40 years, presented with lateral condyle fractures type B1 and B2 ; a 40-year-old female polio victim had a B1 fracture of the medial condyle in the lower limbs ; a 74-year-old male with a B1 fracture of the medial condyle refused surgery.

Surgical treatment consisted of open reduction and fixation using Herbert screws (6), Barr screws together with cancellous screws (2), cannulated screws (5), cancellous screws (4), a compression screw and plate (1), and a stabilizing T-plate (1) in a patient with a fracture line extending proximally.

The surgical technique consisted of a small medial or lateral incision. The condyle was anatomically reduced and temporarily fixed with K-wires ; stable fixation was then achieved with screws or plates.

After surgery, a posterior or articulated splint was used for an average period of 25 days. Continuous passive motion was initiated in all patients after an average of 96 hours. Weight bearing was allowed after a mean period of 70 days.

Follow-up averaged 60 months ; one patient died and two were lost to follow-up. Evaluation was based both on radiological examinations using two standard perpendicular projections and on clinical criteria using Shatzker and Lambert's scoring system (table I).

The four patients who did not undergo surgery were treated with a femoral-malleolar cast with 30° of knee flexion. The cast was worn for an average of 65 days, except for the multiply-injured patient with a B2 fracture, who was surgically treated after 30 days for valgus malunion of the lateral condyle. The three

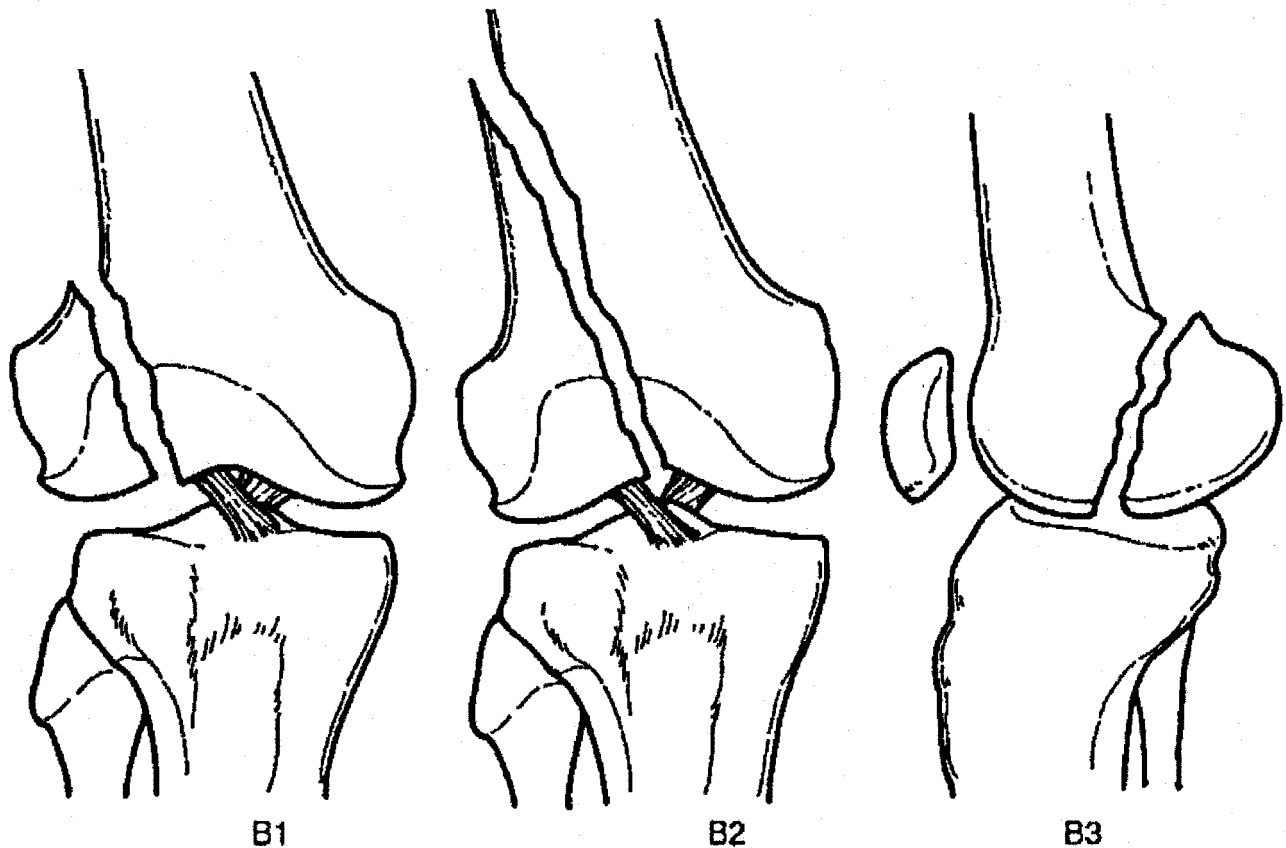


Fig. 1. — AO-ASIF classification of monocondylar femoral fractures

Table I. — Clinical evaluation criteria of results according to Shatzker and Lambert

Results	Notes
Excellent	“No pain, no deformity or incongruence ; loss of flexion < 10° ; full extension”
Good	“Like the excellent result with moderate pain or one of the following parameters ; difference in length > 1.2 cm ; deformity 10° ; loss of flexion > 20° ; loss of extension > 10°”
Fair	Two criteria of the good results
Poor	“Disabling pain or one of the following parameters : deformity > 15° ; maximum flexion 90° ; incongruence of the articular surfaces”

patients treated conservatively underwent rehabilitation with progressive weight bearing after cast removal, and were evaluated at a mean follow-up of 29.3 months using the same method as for surgically treated patients.

RESULTS

Results obtained in surgically treated patients were rated as excellent in 6 cases, good in 5, fair in

4 and poor in one, according to Shatzker and Lambert's classification ; figs. 2-7 illustrate two of these cases.

Radiographic controls allowed evaluation of the degree of fracture healing and of the congruence of the condylar articular surface ; healing time averaged 70 days.

At the first follow-up after 30 days, one patient who had been treated with 2 cancellous screws had

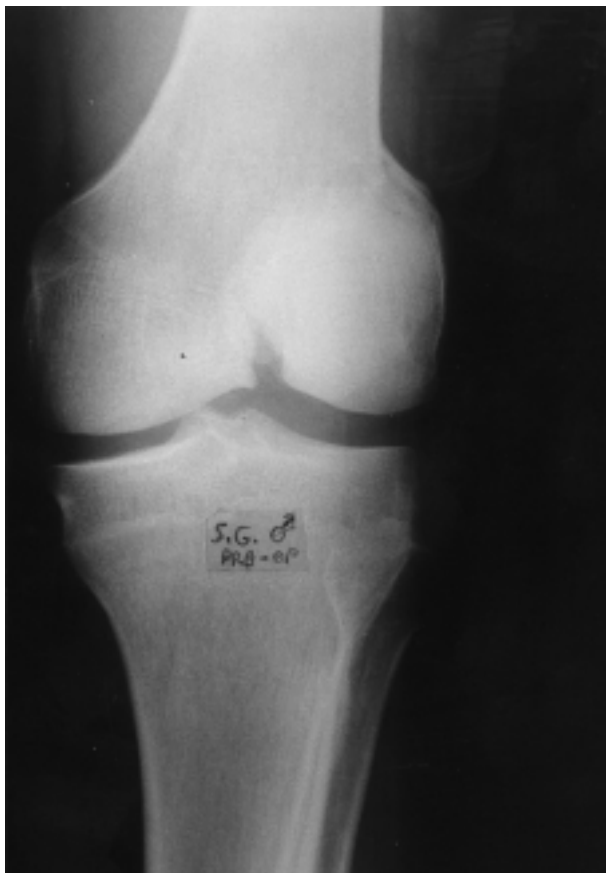

Fig. 2. — Anteroposterior radiograph of B1 fracture of femoral condyle.

loss of congruence of the articular surface and loosening of one of the two screws ; clinically, he had limited flexion-extension of the knee with moderate pain after mobilization. His result was rated poor.

Patients with good or fair results had moderate pain, together with mild or no loss of flexion-extension of the knee. The 5 patients with a Hoffa fracture maintained a satisfactory reduction over time, with 3 excellent and 2 good results ; moreover, no avascular necrosis of the fractured fragment occurred.

Among the 4 cases treated conservatively, the multiply-injured patient with a B2 fracture was operated on after 30 days with placement of a stabilizing T-plate. It was rated as a complete failure ; a clear loss of reduction was identified in the condyle with valgus displacement, together with

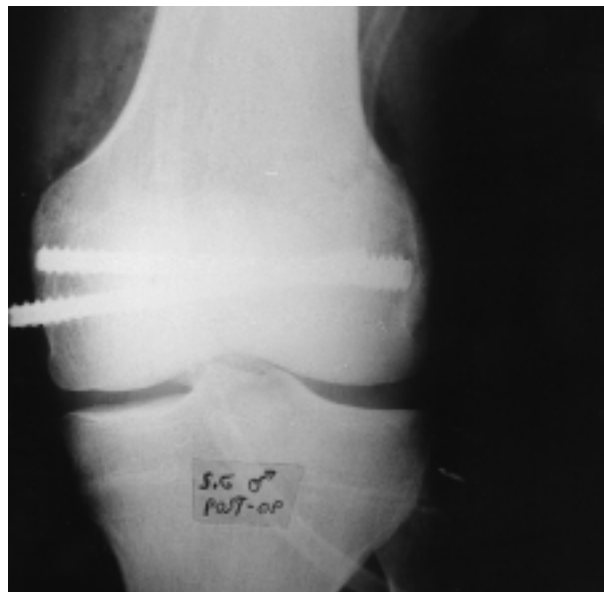

Fig. 3. — Treatment of B1 fracture of femoral condyle with Herbert screws.

nonunion. Fair results were achieved in the remaining 3 patients, with an average healing time of 75 days.

DISCUSSION

In the past, unicondylar femoral fractures were usually treated conservatively with a femoral-malleolar cast. Some authors reported satisfactory results with conservative treatment : for example, the series of 22 patients presented by Kolmert and Wulff (5) in 1982 gave 19 excellent results.

However, available studies lack detailed descriptions of effective fracture reductions and complications related to the length of treatment. In addition, some authors accepted severe short-term limitations of motion (10).

Most unicondylar femoral fractures seem to be displaced as a result of posterior rotation and of valgus or varus deviation with respect to the knee axis, caused by the action of the gastrocnemius muscle (1, 8, 13). To avoid articular incongruity, it is mandatory to obtain an anatomic reduction to prevent axial malalignment and post-traumatic

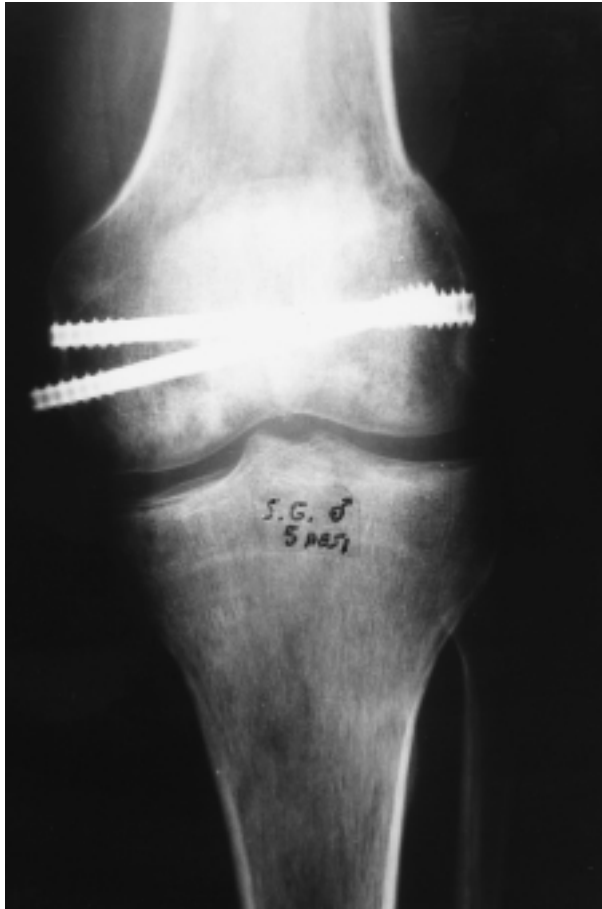

Fig. 4. — Follow-up after five months of B1 fracture treated with Herbert screws.

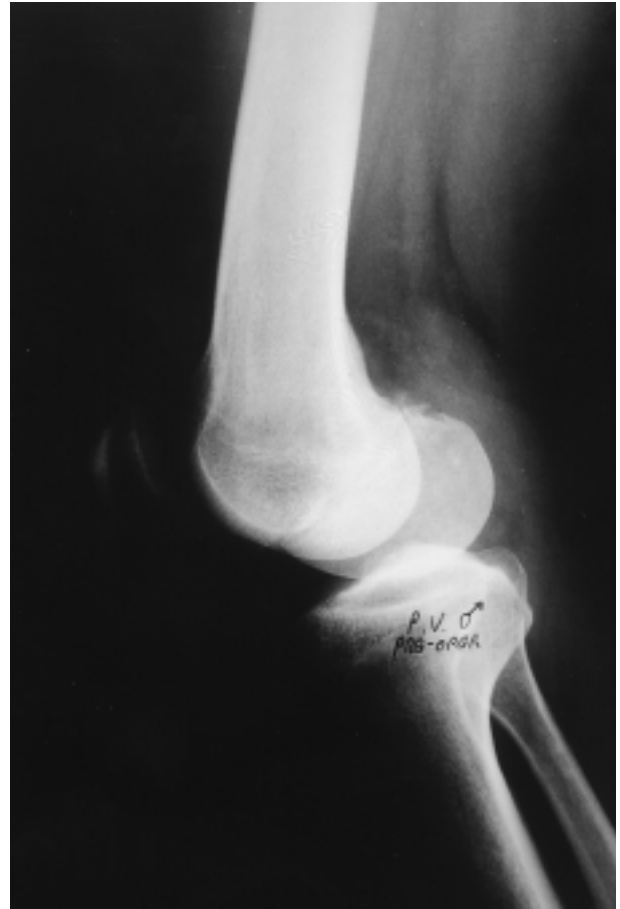

Fig. 5. — Lateral radiograph of B3 fracture of femoral condyle.

arthritis (2, 3, 10). With rare exceptions, it is very difficult to reduce such fractures by closed manipulation, and therefore, open reduction and anatomic reconstruction should be used (3, 7, 9, 10, 13). The B3 fracture, also known as Hoffa's fracture, seems of particular importance: in this case, the only remaining soft tissue attachment is that of the posterior capsule, which behaves as a large intra-articular fragment (3). Traction and nonsurgical methods have no effect on the reduction of this fracture, and surgical treatment is necessary (3, 6). Even the undisplaced fractures have a tendency to secondary displacement caused by muscle contraction and soft-tissue atrophy of the immobilized limb (7, 10). Fractures with proximal extension seem to be particularly unstable: the fracture line

extends towards the metaphysis or proximal diaphysis, and favors the deviation or proximal migration of the fracture. In such cases, the use of either a stabilizing or "anti-sliding" T-plate is helpful (3). The incongruence of the articular line resulting from a displaced fracture and the healing process create a distal modification of the condylar profile (10, 13). This leads to early secondary osteoarthritic changes in femoropatellar and femorotibial compartments (2, 10). Surgical treatment allows for early knee mobilization using continuous passive mobilization devices; such a procedure favors bone revascularization and fracture healing.

Isometric exercises and leg-raising exercises of the extended limb help prevent muscle atrophy and improve functional stability of the joint (12).

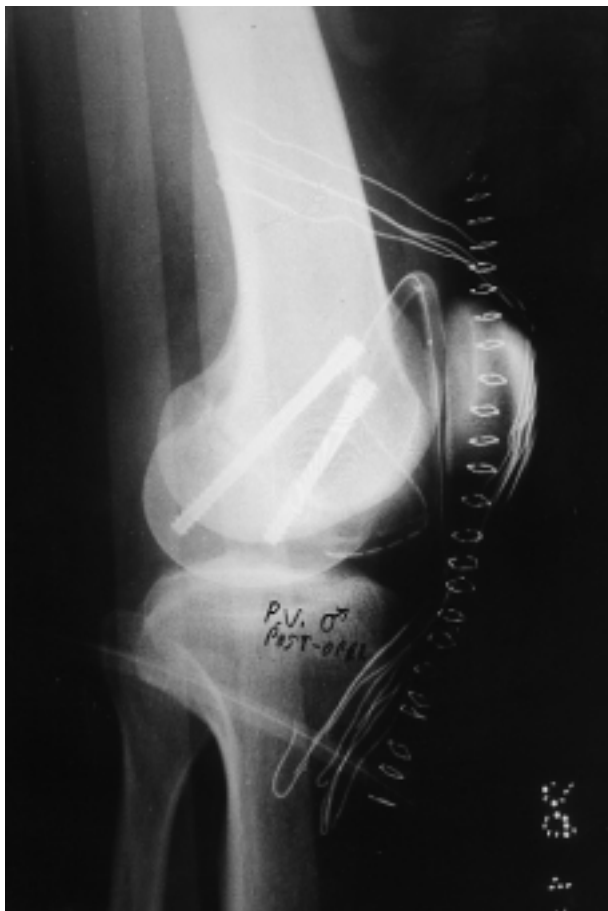

Fig. 6. — Treatment of B3 fracture of femoral condyle with Herbert screws.

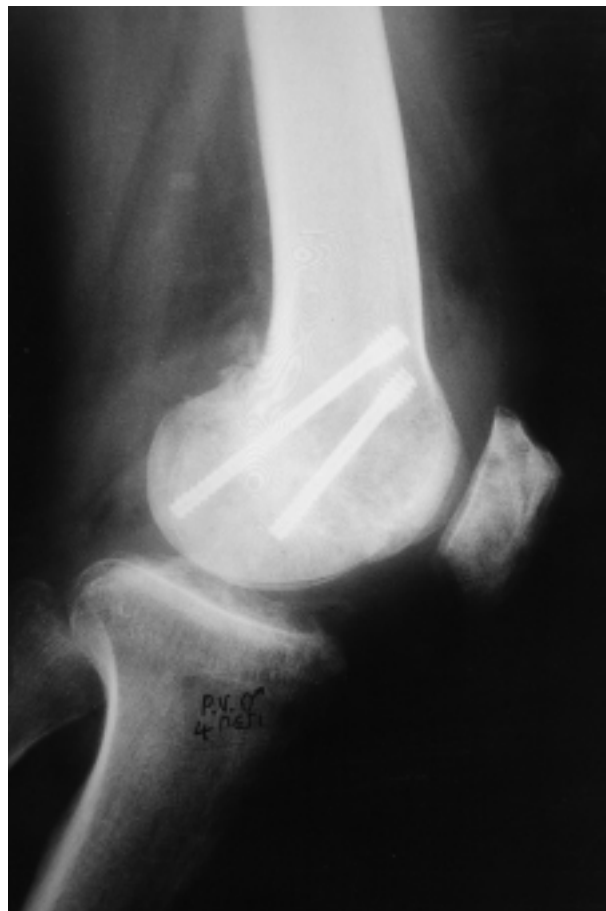

Fig. 7. — Follow-up after four months of B3 fracture treated with Herbert screws.

Even in those cases where nonsurgical treatment seems to be adequate, open reconstruction and rigid internal fixation are essential to promote quick healing, restore good function, ensure early mobilization and avoid late complications (7, 9, 10, 13).

REFERENCES

1. Aglietti P., Buzzi R. Fratture dei condili femorali. In: Insall J. N., ed. *Chirurgia del Ginocchio*. Verduci Editore, Roma, 1995, pp. 939-990.
2. Egund N., Kolmert L. Deformities, gonarthrosis and function after distal femoral fractures. *Acta Orthop. Scand.*, 1982, 53, 963-974.
3. Helfet D. L. Fratture monocondiloidee di femore. vol. 4. In: Browner B. D. *et al.*, ed. *Traumatologia dell'apparato Muscolo-Scheletrico*. Verduci Editore, Roma, 1994, pp. 1721-1765.
4. Kennedy J. C., Grainger R. W., McGraw R. W. Osteochondral fractures of the femoral condyles. *J. Bone Joint Surg.*, 1966, 48-B, 436-440.
5. Kolmert L., Wulff K. Epidemiology and treatment of distal femoral fractures in adults. *Acta Orthop. Scand.*, 1982, 53, 957-962.
6. Letenneur J., Labour P. E., Rogez J. M., Lignon J., Bainvel J. V. Fractures de Hoffa. A propos de 20 observations. *Ann. Chir.*, 1978, 32, 213-219.
7. McCarthy J. J., Parker R. D. Arthroscopic reduction and internal fixation of a displaced intraarticular lateral femoral condyle fracture of the knee. *Arthroscopy*, 1996, 12, 224-227.

8. Nordin J. Y., Masquelet A. C., Gavard R., Signoret F. Les fractures unicondylaires du fémur. Réflexions à partir d'une série de 90 observations. Rev. Chir. Orthop., 1985, 71, Suppl. 2, 111-115.
9. Ostermann P. A., Neumann K., Ekkernkamp A., Muhr G. Long term results of unicondylar fractures of the femur. J. Orthop. Trauma, 1994, 8, 142-146.
10. Smith E. J., Crichlow T. P., Roberts P. S. Monocondylar fractures of the femur : A review of 13 patients. Injury, 1989, 20, 371-374.
11. Strauss E., Nelson J. M., Abdelwahab I. F. Fracture of the lateral femoral condyle. A case report. Bull. Hosp. Joint Dis., 1984, 44, 86-90.
12. Timm K. E. Il ginocchio. In : Richardson J. K., Iglarsh Z. A., ed. Clinica Ortopedica. Terapia Fisica. Verduci Editore, Roma, 1996, pp. 405-409.
13. Trillat A., Dejour H., Bost J., Nourissat C. Les fractures unicondylaires du fémur. Rev. Chir. Orthop., 1975, 61, 611-626.

SAMENVATTING

M. MANFREDINI, A. GILDONE, R. FERRANTE, S. BERNASCONI, L. MASSARI. Therapeutische aanpak en lange termijn resultaten van unicondylaire femurfracturen : studie van 23 gevallen.

De unicondylaire femurfractuur is zeldzaam en komt slechts voor in 0,65% van het aantal fracturen. Er zijn geen diepgaande studies over te vinden in de orthopedische literatuur. De oorzaak is gewoonlijk een sport- of verkeersongeval. De laterale condylus is driemaal meer getroffen dan de mediale. Afhankelijk van het type fractuur wordt ofwel heelkunde ofwel conservatieve therapie aangeraden.

Van 1986 tot 1989 werden 19 patiënten met dergelijke fractuur heelkundig behandeld ; 15 mannen, 4 vrouwen, gemiddelde leeftijd 36,2 jaar. Het AO type was B1 in 7 gevallen, B2 in 6 gevallen en B3 in nog eens 6 gevallen.

Verscheidene osteosynthese materialen werden gebruikt. Herbertschroeven in 6 gevallen, Barr en spongiosaschroeven in 2 gecannuleerde Schroeven in 5, enkel spongiosaschroeven in 4, een tractieschroef met plaatje in 1 en tenslotte een T-plaatje in 1 geval. 16 patiënten

werden met een gemiddelde follow-up van 60 maanden gevolgd en geëvalueerd volgens de criteria van Shatzker en Lambert : 6 waren uitstekend, 5 goed, 4 middelmatig en 1 geval was slecht. Vier gevallen werden conservatief verzorgd : 3 waren matig en 1 geval was slecht. Ons besluit is dan ook dat open reductie en osteosynthese bij deze fracturen te verkiezen zijn.

RÉSUMÉ

M. MANFREDINI, A. GILDONE, R. FERRANTE, S. BERNASCONI, L. MASSARI. Stratégie thérapeutique et résultats à long terme dans les fractures unicondylaires du fémur : étude de 23 patients.

Les fractures unicondylaires du fémur représentent 0,65% de toutes les fractures ; elles n'ont pas fait l'objet d'études approfondies dans la littérature orthopédique. Ces fractures surviennent habituellement suite à des traumatismes sportifs ou des accidents de la voie publique ; elles concernent trois fois plus souvent le condyle latéral que le médial. Le traitement conservateur ou chirurgical a été recommandé en fonction du type de fracture.

De 1986 à 1989, 19 patients présentant une fracture unicondylaire du fémur ont été traités chirurgicalement dans notre service : 15 hommes et 4 femmes, dont l'âge moyen était de 36,2 ans. Selon la classification de l'AO, il y avait 7 fractures de type B1, 6 de type B2 et 6 de type B3. L'ostéosynthèse a été réalisée avec des vis de Herbert dans six cas, des vis de Barr et des vis à spongieux dans deux cas, des vis canulées dans 5 cas, des vis à spongieux dans 4 cas, par une vis de rappel et une plaque dans un cas et par une plaque en T dans le dernier. Dans le même temps, 4 patients ont été traités orthopédiquement. Seize patients traités chirurgicalement ont été évalués après un suivi moyen de 60 mois, sur base des critères de Shatzker et Lambert : 6 résultats ont été classés comme excellents, 5 comme bons, 4 comme moyens et un comme mauvais, tandis que le traitement conservateur a donné trois résultats moyens et un mauvais. En conclusion, nous pensons que le traitement chirurgical par réduction sanglante et ostéosynthese s'impose dans le traitement de ces fractures.