

SURGICAL TREATMENT FOR RHEUMATOID NECK ARTHRITIS BILATERAL OCCIPITOSPINAL FUSION WITH PLATE FIXATION

A.A. FARAJ¹, J.K. WEBB¹, H. PRINCE¹

The results of surgical treatment of 12 patients with rheumatoid cervical spine arthritis were reviewed. The Ranawat classification was as follows : 5 with Ranawat IIIB, 1 Ranawat IIIA and 6 Ranawat II. Decompression and fusion using autogenous iliac bone graft and double occipitospinal plate fixation was carried out on 11 of these patients; the remaining patient underwent upper cervical spine fusion using screw and wire fixation. The main indication for surgery was neurological deterioration. In three cases previous surgery had been carried out on the cervical spine.

The results were assessed at a mean follow-up of 26.1 months. According to Frankel's grading the neurological recovery in patients with neurological compression was one grade. There was clinical and radiological evidence of fusion in all these patients. The following complications required further surgery :

- acute postoperative epidural hematoma (one patient)
- screw loosening (one patient)

Conclusion : Fusion of the occiput and lateral mass of the involved cervical spine using a plate on each side provides a relatively stable fixation in patients with rheumatoid arthritis of the cervical spine. Laminectomy and adequate decompression of the neural elements can be carried out without compromising spinal stability.

There is a relatively high complication rate associated with surgery for rheumatoid neck and the patient needs to be informed.

Key words : rheumatoid arthritis ; cervical spine ; fusion.

Mots clés : arthrite rhumatoïde ; rachis cervical ; arthro-dèse.

INTRODUCTION

The cervical spine is involved in up to 90 % of cases of longstanding systemic rheumatoid arthritis (4). The onset of neurological impairment is usually gradual and is overlooked or attributed to other joint disease. The commonest instability is atlanto-axial ; however, subaxial subluxation is not uncommon (1,2,4).

The aim of the current study was to assess the surgical outcome of cervical spine decompression and stabilization for rheumatoid arthritis of the spine.

MATERIAL AND METHODS

Twelve patients (10 female, 2 male) with a mean age of 58.2 years (42-80) were treated in the Centre for Spinal Study and Surgery between 1991 and 1995 for rheumatoid cervical spine arthritis. All these patients had the disease for a mean period of 13.4 (2-28) years. All of these patients had systemic involvement, among which seven patients had had previous orthopedic operations like joint arthroplasty and hand reconstructive surgery for rheumatoid disease.

¹ Centre for Spinal Study and Surgery, University Hospital, Nottingham, UK

Correspondence and reprints : Mr. A.A Faraj, 28 Colston Close, Crow Tree Lane, Bradford BD8 0BN, United Kingdom
Email: adnanfaraj@hotmail.com

Rheumatologists referred nine patients after the failure of medical treatment including systemic steroids to relieve neurological compression of the cervical spine. The onset of neurological compression was insidious. The remaining three had failed cervical spine surgery in the past to relieve neurological compression. Among these Gallie fusion had been carried out in two and transoral anterior upper cervical decompression and posterior Gallie fusion, in one.

The indication for surgery was to prevent impending neurological compression in 6 patients and to stabilize the spine for future intubation and anesthesia in another 6 (table I).

Table 1. — Ranawat classification of our patients with rheumatoid cervical spine disease

Ranawat	Grade II	Grade IIIA	Grade IIIB
Clinical Status	Ambulatory Subjective weakness	Ambulatory Objective weakness	Nonambulatory Objective weakness
No. of patients	6	1	5

All these patients had both anteroposterior and flexion extension lateral cervical spine radiographs together with magnetic resonance imaging (MRI) of the spine to elucidate the level and severity of cervical spine cord compression. All these patients had atlantoaxial subluxation (AAS); in addition to this 11 had associated subaxial subluxation (SAS).

The mean erythrocyte sedimentation rate (ESR) in these patients was 45 (20-100) mm/hr.

Prior to surgery, three of these patients required a halo vest for a mean period of 25 days (20-60 days) in an attempt to reduce the subluxation of the cervical spine.

OPERATIVE TECHNIQUES

The operation was carried out under general anesthesia with the patient prone and the head resting on a headpiece with a window for the nasotracheal tube. A halo was applied in all these patients

during surgery in order to reduce and maintain the reduction of spinal subluxation during surgery. The procedure was carried out through a midline occipitocervical longitudinal incision with the cervical spine flexed to facilitate the access. After proper decompression of the neural elements and spinal canal through multiple minilaminectomies, C1-C2 transarticular screws were used under fluoroscopy to stabilize the C1-C2 subluxation. Posterolateral cervical spine fusion was performed using iliac bone graft and two lateral titanium occipitospinal plates for fixation (fig. 1). The plates were contoured to the occipitocervical area after reduction of the cervical subluxation. The occipital fixation was stabilized with screws through the plate fixed to the lateral mass on each side of the spine. Table II shows various procedures performed in our patients.

The halo at the end of the operation was attached to a vest. This was kept for 8 to 10 weeks in the postoperative period.

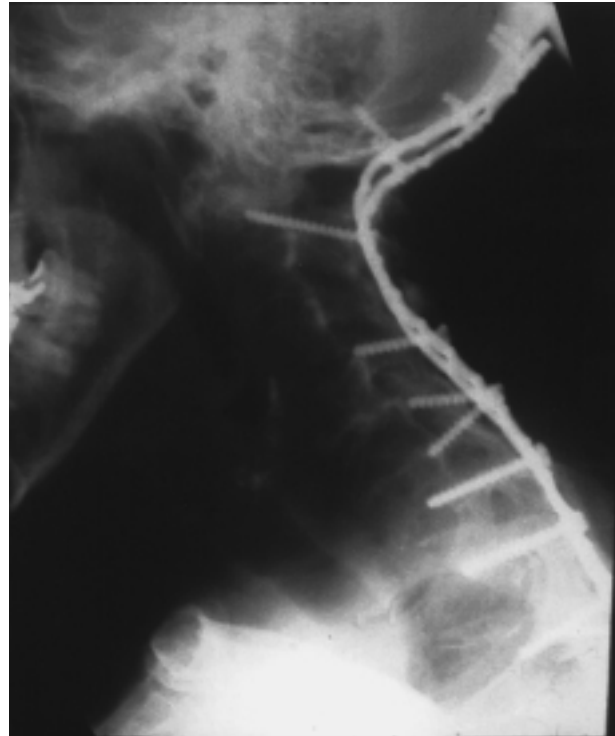


Fig 1. — Lateral radiograph of a patient with occipitocervical fusion for rheumatoid neck disease.

Table II. — Showing various procedures carried out for patients with rheumatoid cervical spine disease in this series

Procedure	Number of patients
Occipitocervical fusion	5
Occipitothoracic fusion	6
Posterior Gallie fusion	1
Autogenous iliac bone graft fusion	12
Total number of patients	12

RESULTS

The assessment included the neurological recovery, evidence of fusion and record of complications following surgery. The mean period of follow-up was 26.1 months (6-48 months). The neurological recovery in five patients with Frankel C (incomplete motor function, grade 1-2/5) was one grade (Frankel D; fair to good motor function, grade 3-4/5).

Radiological signs of fusion were difficult to assess because of the implant, the quality of bone and multilevel involvement of the spine. At final follow-up, there was clinical and radiological evidence of cervical spine fusion.

The following complications were encountered :

1. Acute epidural hematoma of the cervical spine : this patient's neurological status deteriorated over the first 24 hours after surgery. MRI scan of the cervical spine showed an epidural hematoma. It was immediately drained, but the outcome was poor. He remained wheelchair-bound because of neurological impairment.

2. Acute myocardial infarction in one case : this patient was treated in the coronary care unit until the condition stabilized.

3. Superficial wound infection (1) responded to a course of antibiotics.

4. Loose C5 lateral mass screws in one case, three months after the operation: the occipitocervical fusion was extended into occipitothoracic (T1) fusion.

DISCUSSION

Surgery may not be successful in reversing significant neurological deterioration (Ranawat IIIB)

(4). Complications include pseudoarthrosis (20%) and recurring myelopathy (1,2,5). Extending the fusion to the occiput may lessen the pseudoarthrosis rate (1, 2, 3, 5).

Numerous different implants have been presented in the literature for occipitocervical in patients with rheumatoid arthritis. The use of wires remains the standard fixation technique. To obtain a stable wire fixation, the laminae have to be left intact ; decompression of the neural elements therefore can be done only with laminoplasty. Laminoplasty is difficult to perform safely in an osteopenic skeleton. With lateral mass plate occipitospinal fusion, adequate decompression of neural elements is feasible through multiple minilaminectomy.

Iatrogenic neurological injury and incidence of pseudoarthrosis following fusion is higher using sublaminar wiring compared to other techniques (3). An incidence of 27% pseudoarthrosis was reported using sublaminar wiring compared to only 6% using a plate and screw fixation system (3). Double lateral plate fixation allows an easy approach to the midline structures of the spine as compared to Y shaped plate fixation used for the same purpose (3). Titanium plate for fixation does not interfere with MRI, which occasionally is necessary after the operation to exclude hematoma and other conditions.

CONCLUSION

In conclusion, we recommend using lateral mass occipitospinal fixation when performing fusion of the cervical spine in patients with rheumatoid arthritis because of the mechanical stability it offers and the easy access of the laminae for neurological decompression. We also recommend extending the fusion to the relatively normal segment of spine when the quality of bone is poor. The reoperation rate in our series was 16%.

REFERENCES

1. Boden S.D., Dodge L.D., Bohlman H.H., Rehtine G.R. Rheumatoid arthritis of the cervical spine. A long term analysis with predictors of paralysis and recovery. *J. Bone Joint Surg.*, 1993, 75-A, 1282-1297.

2. Clark C.R., Goetz D.D., Menezes A.H. Arthrodesis in cervical spine in rheumatoid arthritis. *J. Bone Joint Surg.*, 1989, 71-A, 381-392.
3. Grob D., Dvorak J., Panjabi M.M., Antinnes J.A. The role of plate and screw fixation in occipitocervical fusion in rheumatoid arthritis. *Spine*, 1994, 19, 2545-2551.
4. Ranawat C.S., O'Leary P., Pellicci P., Tsairis P., Marchisello P., Dorr L. Cervical spine fusion in rheumatoid arthritis. *J. Bone Joint Surg.*, 1979, 61-A, 1003-1010.
5. Zoma A., Sturrock R.D., Fisher W.D., Freeman P.A., Hamblen D.L. Surgical stabilization of the rheumatoid cervical spine. *J. Bone Joint Surg.*, 1987, 69-B, 8-12

SAMENVATTING

A. A. FARAJ, J. K. WEBB, H. PRINCE : Heelkundige behandeling van reumatoïde misvormingen van de cervicale zuil : occipitospinale fusie met twee laterale platen.

De resultaten van heelkunde bij 12 patiënten met een reumatische aantasting van de cervicale zuil werden nagekeken. Volgens de Ranawat classificatie bevonden zich 5 gevallen in klasse IIIB, 1 en IIIA en 6 in II. De behandeling bestond bij 11 gevallen in decompressie en fusie bij middel van iliacaal botenten en een dubbele laterale occipito-spinale osteosyntheseplaat ; in het overblijvend geval werd een hoge cervicale fusie verricht met vijzen en cerclage draad.

Er was al heelkunde aan voorafgegaan in drie gevallen. De gemiddelde follow-up was 26,1 maanden.

Het neurologisch herstel in de evaluatie volgens Frankel bedroeg een graad. Klinische en radiologische fusie werd bereikt in alle gevallen. Secondaire heelkunde was noodzakelijk eenmaal wegens postoperatief epiduraal haematoom, en eenmaal wegens loskomen van een schroef.

We besluiten dat occipitocervicale fusie met een plaat langs beide zijden op de laterale cervicale massa's een behoorlijk stevige fixatie geeft bij patiënten met reumatoïde arthritis van de cervicale wervelzuil. De neurale elementen kunnen gedeprimeerd worden door gelijktijdige laminectomie zonder de stabiliteit van de

montage te schaden. De patiënten moeten worden verwittigd dat er een vrij hoge kans op verwikkelingen bestaat bij dergelijke chirurgie.

RÉSUMÉ

A. A. FARAJ, J. K. WEBB, H. PRINCE : Traitement chirurgical du rachis cervical rhumatoïde : arthrodèse occipito-rachidienne avec fixation par plaque bilatérale.

Les auteurs ont étudié le résultat du traitement chirurgical réalisé chez 12 patients qui présentaient une atteinte rhumatoïde du rachis cervical. Selon la classification de Ranawat, il y avait 5 patients Ranawat IIIB, 1 Ranawat IIIA et 6 Ranawat II. Onze patients ont subi une décompression et une arthrodèse réalisée avec des greffes iliaques autogènes et une fixation par plaque occipito-rachidienne bilatérale ; le dernier patient a subi une arthrodèse cervicale haute avec fixation par vis et par cerclages. L'indication majeure du traitement chirurgical était la détérioration neurologique. Trois patients avaient déjà subi des interventions antérieures sur le rachis cervical. Les résultats ont été évalués avec un suivi moyen de 26,1 mois. Selon la classification de Frankel, la récupération neurologique chez les patients qui présentaient une compression neurologique a été de un degré. Sur base des éléments clinique et radiologique, la fusion a été obtenue dans tous les cas. Les complications suivantes ont imposé un nouveau geste chirurgical : hématome épidural aigu en post-opératoire chez un patient, descellement des vis chez un autre.

En conclusion, l'arthrodèse occipito-cervicale avec fixation par une plaque de chaque côté assure une fixation relativement stable chez ces patients qui présentent une atteinte rhumatoïde du rachis cervical. Cela permet de réaliser une laminectomie et une décompression adéquate des éléments nerveux sans compromettre la stabilité du rachis. Il y a cependant un taux de complications relativement élevé pour cette chirurgie du rachis cervical rhumatoïde, dont le patient doit être prévenu.