

CASE REPORTS

NEUROFIBROMATOSIS, GIGANTISM, ELEPHANTIASIS NEUROMATOSA AND RECURRENT MASSIVE SUBPERIOSTEAL HEMATOMA : A NEW CASE REPORT AND REVIEW OF 7 CASE REPORTS FROM THE LITERATURE

F. STEENBRUGGE, B. POFFYN, D. UYTENDAELE, R. VERDONK, K. VERSTRAETE¹

The authors report the case of a 13-year-old patient with neurofibromatosis (NF-I), who suffered blunt trauma to the left tibia in 1993. The diagnosis of subperiosteal hematoma was made. Treatment consisted of temporary rest. There was a recurrence in 1996, and the subperiosteal hematoma was drained. In 1997, a shortening osteotomy of the left tibia was performed. However, massive gigantism with elephantiasis of the left leg remained, causing a serious functional and cosmetic problem. In 1999, the leg was amputated above the knee. The literature is reviewed and 7 case reports are compared. The pathogenesis of subperiosteal hematoma is discussed.

Keywords : neurofibromatosis ; gigantism ; subperiosteal hematoma.

Mots-clés : neurofibromatose ; gigantisme ; hématome sous-périosté.

INTRODUCTION

Neurofibromatosis classically presents as hyperpigmentation, known as café-au-lait spots, and multiple neurofibromas. The musculoskeletal system is affected in 50% of patients and common abnormalities include short-segment angular scoliosis, pseudarthrosis of the tibia, and partial or total limb gigantism. A rarer manifestation or, more specifically, complication of neurofibromatosis is massive subperiosteal hemorrhage, the ultimate radiologic appearance of which is that of a subperiosteal or cortical bone cyst.

This case demonstrates a rare musculoskeletal abnormality of neurofibromatosis: the triad of limb hypertrophy, recurrent subperiosteal hemorrhage without trauma and subsequent subperiosteal new bone formation.

CASE REPORT

E.C. was born in 1981 after a normal pregnancy. Her mother had type I neurofibromatosis (NF-I). Clinical examination after birth showed congenital hypoplasia of the right lower limb and hypertrophy of the left lower limb. Several café-au-lait spots were seen at birth, and the diagnosis of NF-I was made. She first presented to the orthopedics department in 1985 because of a leg length discrepancy of 5 cm. An elongation procedure of the right tibia was performed using the Ilizarov external fixator method. On the left lower limb a very painful neurofibroma was present involving the lateral aspect of the fibula. The mobility of the left and right knee joint was normal after this procedure. Because of a progressive length discrepancy of 12 cm, percutaneous epiphysiodesis of the left distal femur was performed in 1991. Nevertheless, a difference in

Department of Orthopedic Surgery and ¹Department of Radiology, Ghent University Hospital, B-9000 Gent, Belgium.

Correspondence and reprints: F. Steenbrugge, Department of Orthopedic Surgery and Trauma, UZ-Gent, De Pintelaan 185, B-9000 Gent, Belgium.

length of 8 cm persisted at the end of growth. In February 1993, the girl suffered minor blunt trauma to the left tibia. She complained of fluctuating pain at night, local tenderness and swelling at the anteromedial distal third of the lower leg.

Plain xrays, ultrasonography, Tc-bone scanning, CT-scanning and MRI were performed four weeks after the trauma. The xrays showed a single-layer elliptical periosteal elevation (fig. 1), but no fracture. CT-scanning disclosed a fusiform, wavy, single-layer periosteal calcification on the medial aspect of the tibia (fig. 2). Ultrasonography demonstrated the presence of a hematoma, 3 cm in diameter and 6 cm in length, in the soft tissues of the calf. On Tc-bone scanning a fusiform area of increased bone turnover activity was found on the medial aspect of the tibia (fig. 3). MRI showed a

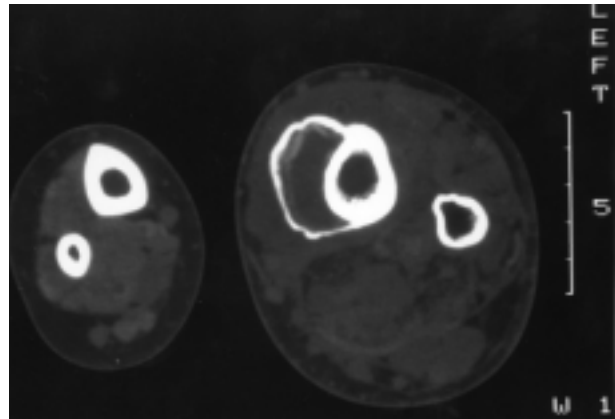


Fig. 2. — CT-scan of the lower legs shows a hypoplastic right and a hypertrophic left lower leg, and elevation of the periosteum of the left tibia. Note the beginning ossification in the periphery of the subperiosteal hematoma.

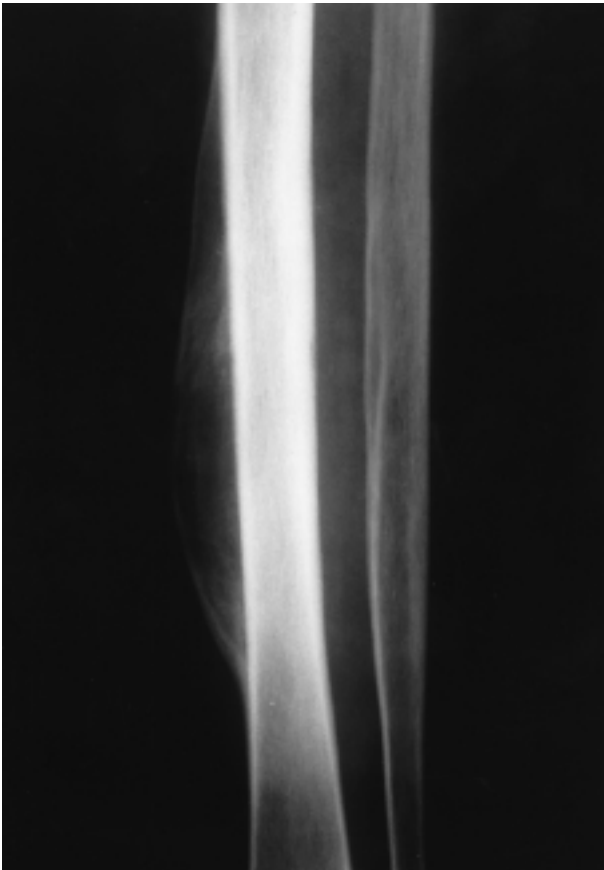

Fig. 1. — Anteroposterior xray of the left lower leg shows an elliptical periosteal elevation, with hour-glass appearance, typical of subperiosteal hematoma.

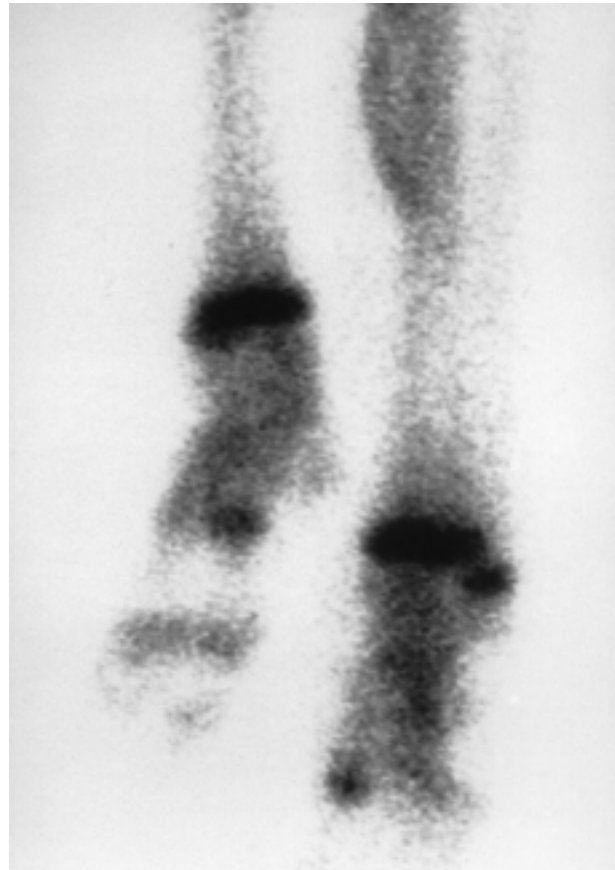


Fig. 3. — Tc-bone scan shows a fusiform area of increased bone activity at the medial aspect of the left tibia.

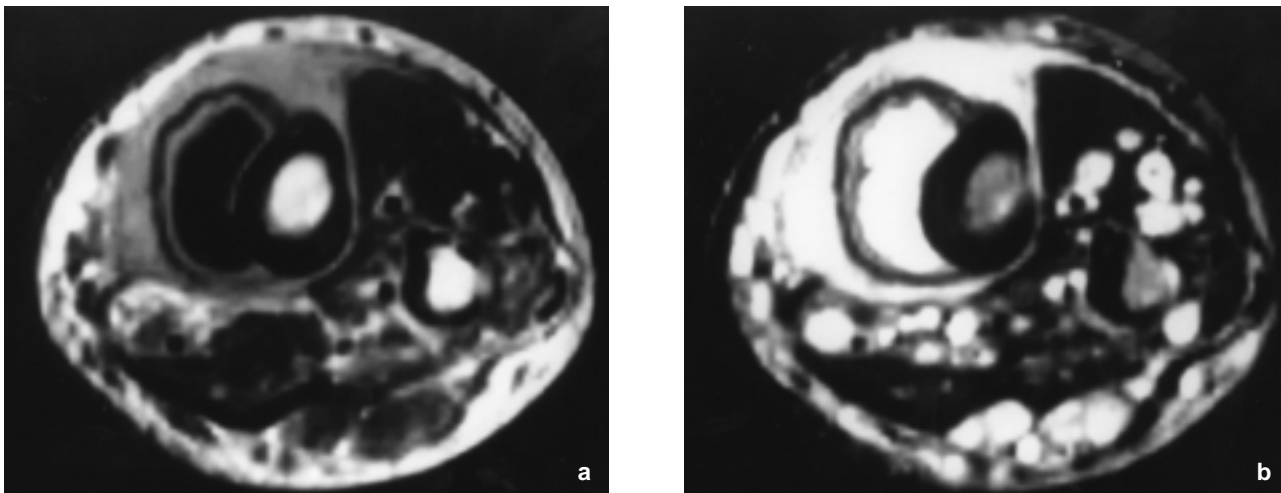


Fig. 4. — MRI of the left lower leg (axial T1-weighted (a) and T2-weighted image).

The periosteum is visible as a black line, elevated from the tibia. It is surrounded by edema in the soft tissues (light gray in a and white in b). The liquified hematoma is indicated with an asterisk. Note the white rounded neurofibromas in the anterior and posterior muscle compartment (b).

single-layer periosteal bone apposition on the anteromedial aspect of the tibia, surrounded by soft tissue edema. It contained an old liquified hematoma surrounded by a contrast-enhancing wall of granulation tissue (fig. 4 a, b). Multiple small neurofibromas were detected in the anterior and posterior muscle compartment. The laboratory findings were normal. The diagnosis of subperiosteal hematoma was made. Treatment consisted of temporary rest and follow-up at regular intervals, but a small lump remained on the anteromedial aspect of the left tibia. In 1996 this swelling of the left lower limb suddenly increased without trauma and a mass was palpable in the popliteal fossa. A follow-up MRI revealed the presence of a neurofibroma in the popliteal fossa and a new subperiosteal hematoma on the anterior and posterior aspect of the tibia. There was also extensive edema. Drainage of the subperiosteal hematoma was performed. The pathologic report confirmed the earlier diagnosis. There were no signs of malignancy. Further xray and MRI investigations were done at regular intervals, showing progressive ossification and shrinkage of the hematoma. After several years only a slightly elevated, fusiform thickening of the cortex remained at the site of the former subperiosteal hematoma. In 1997, a shortening osteotomy of the

left tibia was performed. However, massive gigantism with elephantiasis of the left leg remained, causing a major functional and cosmetic problem. In 1999, the left leg was amputated above the knee.

DISCUSSION

Subperiosteal hematomas of the lower extremities are associated with bone matrix defects (scurvy or osteogenesis imperfecta), severe periosteal trauma (battered child syndrome), or neuromuscular deficiencies (congenital insensitivity to pain or meningomyelocele). Neurofibromatosis is a congenital and familial disorder, characterized by neuroectodermal (skin and nervous system) and mesodermal (bone and cartilage) abnormalities. Mesodermal dysplasia, including pseudarthrosis, gigantism, hypoplasia, and kyphoscoliosis, accounts for 65% of the manifestations of neurofibromatosis (1). Another expression of mesodermal dysplasia is abnormal loose periosteum and subsequent subperiosteal hemorrhage (5). The occurrence of poor callus response in the region of a congenital pseudarthrosis is also an example of abnormal periosteum in neurofibromatosis. The radiographic characteristics of subperiosteal hematoma in newborns who develop cephalohematomas secondary

to birth trauma (7) have been described extensively. Peripheral curvilinear calcifications usually develop 10 to 14 days following the initial presentation of the hematoma. Gradually, the calcified periphery increases as the hematoma is organized and resorbed. At four to six weeks, radiographs may show a thick, crescentic, peripheral calcification surrounding the uncalcified, irregular, radiolucent center. Eventually, the area becomes less apparent. A similar phenomenon can take place in subperiosteal hemorrhages involving the long bones in patients with neurofibromatosis.

A review of the literature (2, 3, 4, 6, 8) revealed 7 case reports.

In 1969 Smithuis reported on a case of subperiosteal hematoma of the tibia, which had occurred after minor trauma. Biopsy of the thickened bone and overlying tissues showed normal periosteum covered by fibrous subcutaneous fatty tissue (6). Kullmann and Wouters (3) described two cases (1 tibia and 1 femur). They mentioned vascular dysplasia, neurogenic factors, mesodermal dysplasia or congenital developmental disturbance as possible causative factors for the gigantism and elephantiasis. They assumed that in their two patients, in whom subperiosteal hemorrhage occurred in a limb with looseness of the soft tissues, the connection between periosteum and the underlying bone was abnormally loose. Lack of resistance of the periosteal sheath may have been responsible for overgrowth. In one case this theory was strengthened by the observation that a silent fracture without displacement produced very extensive elevation of the periosteum with extensive local callus formation. Moreover, the fact that subperiosteal hemorrhage seemed to occur predominantly in children, in whom the periosteal sheath is normally less adherent to the underlying bone than in adults, supported this idea. They found five similar cases in the literature (3).

Yaghmai *et al.* reported on two cases of massive subperiosteal hemorrhage after relatively minor trauma (8). They advanced several hypotheses to explain these findings. The presence of subperiosteal infiltration by neurofibromatous tissue may result in loosening of the periosteal attachment to bone. In cases of minor trauma, massive subpe-

riosteal hematoma may then occur. They felt that defective bone formation is responsible for bone changes in neurofibromatosis, but its cause is unknown.

The absence of neurofibromatous tissue in association with most intraosseous cyst-like lesions, pseudarthrosis, and in the slender delicate bones that usually accompany elephantiasis neuromatosa, suggests that mesodermal dysplasia may be the underlying cause of these bone changes. Observations by Pitt *et al.* (5) of the presence of loose periosteum in cases of neurofibromatosis suggested that this may be a primary manifestation of mesodermal dysplasia, and does not always result from subperiosteal infiltration by neurofibromatous tissue as described above. Secondary causes unrelated to basic disease, such as trauma, infection, tumor, may cause periosteal elevation, and in the case of trauma, subperiosteal hemorrhage.

Owing to defective loose periosteum, minor injury could cause massive hemorrhage.

Mandell *et al.* (1986) demonstrated that the subperiosteal hematoma in a tibia was a scintigraphic "doughnut". The "doughnut" sign had been described frequently in brain and skeletal scintigraphy, but not previously in a subperiosteal hematoma associated with neurofibromatosis and focal gigantism. They concluded that subperiosteal hematoma in neurofibromatosis in association with local gigantism was the result of mesodermal dysplasia.

The scintigraphic "doughnut" configuration (a peripheral rim of increased activity surrounding a relatively photopenic center) of the subperiosteal hematoma could precede the characteristic appearance of the gross calcification on radiographic examination. The clinical and imaging findings permit differentiation of subperiosteal hematoma from abscess or tumor (4). Huk *et al.* (1991) mentioned a recurrent massive subperiosteal hemorrhage in the femur of a patient with neurofibromatosis. The diagnosis was confirmed by plain radiography, ultrasonography and computed tomography (2). All seven patients in these case reports also presented gigantism of the affected limb. The subperiosteal hematoma was always the result of minor trauma. Its recurrent nature was also

a constant finding. Clinical, imaging, pathologic and laboratory findings were consistent with our results. In two cases, an above-knee amputation was performed because of the grotesque limb deformity. In conclusion, subperiosteal hematomas can occur in neurofibromatosis in association with local gigantism as a result of mesodermal dysplasia. The correlation between the clinical and imaging findings allows differentiation of subperiosteal hematoma from abscess or tumor. In general no specific treatment is necessary for subperiosteal hematoma, as resorption is the natural course. Therapeutic options are temporary rest and follow-up at regular intervals or drainage of the hematoma for pain relief. Treatment of gigantism is dependent on the nature of the presenting deformity. Excision of the hypertrophied soft tissue and nodular masses may be indicated. Amputation of grotesque or gigantic digits or limbs improves the appearance and function.

REFERENCES

1. Casselman E. S., Miller W. T., Lin S. R. Von Recklinghausen's disease : Incidence of roentgenographic findings with a clinical review of the literature. *CRC Crit. Rev. Diagn. Imaging*, 1977, 9, 387-390.
2. Huk O., Newman N., Fowles J. Y. Recurrent massive subperiosteal hemorrhage in a patient with neurofibromatosis : A case report. *Can. J. Surg.*, 1991, 34, 259-262.
3. Kullmann L., Wouters H. W. Neurofibromatosis, gigantism and subperiosteal hematoma. *J. Bone Joint Surg.*, 1972, 54-B, 130-138.
4. Mandell G. A., Harcke H. T. Subperiosteal hematoma. Another scintigraphic "doughnut". *Clin. Nucl. Med.*, 1986, 11, 35-37.
5. Pitt M., Mosher J. F., Ediken J. Abnormal periosteum in bone in neurofibromatosis. *Radiology*, 1972, 103, 143-146.
6. Smithuis T. Subperiosteal hematoma of the tibia : Report of a case. *J. Bone Joint Surg.*, 1969, 51-B, 130-131.
7. Swischuk L. E. *Radiology of the Newborn and Young Infant*. Baltimore, Williams and Wilkins, 1980, pp. 799-800.
8. Yaghmai I., Tafazoli M. Massive subperiosteal hemorrhage in neurofibromatosis. *Radiology*, 1977, 122, 439-441.

SAMENVATTING

F. STEENBRUGGE, B. POFFYN, D. UYTTENDAELE, R. VERDONK, K. VERSTRAETE. Neurofibromatose, gigantisme, elephantiasis neuromatosa en recidiverend massief subperiostaal hematoom : een nieuw case-report en een nazicht van 7 case-reports in de literatuur.

De auteurs beschrijven een dertienjarige patiënte met neurofibromatosis (NF-I) die een stomp trauma opliep ter hoogte van de linkertibia in 1993. De diagnose van subperiostaal hematoom werd gesteld. De behandeling bestond uit tijdelijke rust. Er was een recidief in 1996 en het subperiostaal hematoom werd gedraineerd. In 1997 werd er een verkortingsosteotomie van de linker tibia uitgevoerd. Desalniettemin bleef er een massief gigantisme met elephantiasis van het linker onderste lidmaat bestaan en dit veroorzaakte een ernstig functioneel en cosmetisch probleem. In 1999 ging men over tot een amputatie van het been boven de knie. De literatuur werd nagekeken en een vergelijking werd gemaakt met 7 andere case reports.

RÉSUMÉ

F. STEENBRUGGE, B. POFFYN, D. UYTTENDAELE, R. VERDONK, K. VERSTRAETE. Neurofibromatose, gigantisme, éléphantiasis neuromatosa et hématome sous-périosté récidivant : présentation d'un cas et revue de 7 cas publiés.

Les auteurs rapportent le cas d'une patiente de 13 ans atteinte de neurofibromatose (NF-I) qui a subi un traumatisme au niveau du tibia gauche en 1993. On a diagnostiqué un hématome sous-périosté, et le traitement a consisté en une mise au repos temporaire. Elle a présenté une récurrence en 1996 ; l'hématome sous-périosté a été drainé. En 1997, elle a subi une ostéotomie de raccourcissement du tibia gauche. Cependant, elle présentait toujours un gigantisme impressionnant du membre avec éléphantiasis, responsable d'une gêne fonctionnelle et esthétique importante. Elle a finalement subi une amputation au-dessus du genou en 1999. Les auteurs présentent une revue de la littérature et comparent les 7 cas qui ont été rapportés. Ils discutent la pathogénie de l'hématome sous-périosté.