

## CASE REPORT

# SUBTALAR ARTHRITIS AS A PRESENTING SYMPTOM OF FAMILIAL MEDITERRANEAN FEVER : CASE REPORT AND LITERATURE REVIEW

I. DUDKIEWICZ, A. CHECHIK, A. BLANKSTEIN, M. SALAI

**Familial Mediterranean fever (FMF) is an autosomal, recessive disease affecting mainly people of Mediterranean origin. The primary pattern of FMF is acute, self-resolving periodic attacks of high-grade fever, accompanied by either peritonitis, pleuritis, or arthritis and sometimes typical ankle rash that simulates erysipelas. Rare manifestations, such as pericarditis or massive knee effusion, have been reported in the literature as a presenting symptom of FMF. The final diagnosis has recently become more accurate by identification of the gene for FMF. We describe a unique presenting symptom of subtalar arthritis with no former personal or family history of FMF. A genetic evaluation revealed a 694/726 genetic variant that confirmed the diagnosis of FMF. Treatment with daily colchicine, 1 mg/day, resulted in complete resolution of all complaints.**

**Keywords :** subtalar arthritis ; familial Mediterranean fever.

**Mots-clés :** arthrite sous-astragalienne : fièvre méditerranéenne familiale.

---

### INTRODUCTION

Familial Mediterranean fever (FMF), also known as hereditary recurrent polyserositis, is an autosomal recessive disease that affects mainly people of Mediterranean origin. The dominant pattern of FMF is an acute, self-resolving periodic attack of high-grade fever, accompanied by either peritonitis, pleuritis, or arthritis, and sometimes typical ankle rash that simulates erysipelas.

In the past the disease, as expressed by its name, was limited to the Mediterranean area, but today is

spread throughout the world. It is still most prevalent among the Mediterranean and Middle Eastern populations, especially in non-Ashkenazi Jews (North Africans (11), Iraqi (7), as well as those of Turkish origin and even Ashkenazi (central or eastern European origin or ancestry) Jews. The new spread of the disease makes diagnosis extremely difficult.

Certain rare manifestations have been reported in the literature as a presenting symptom of FMF, among which are pericarditis, and massive knee effusion (9).

A unique case of a young patient with an atypical appearance of FMF with subtalar arthritis as a presenting symptom is reported here, with a short review of the literature.

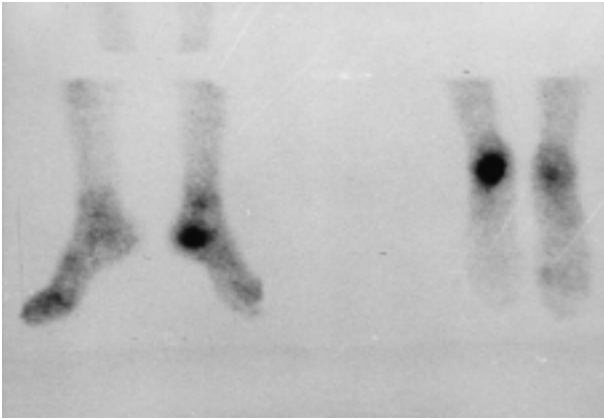
### CASE REPORT

A. L., a 25-year-old male who was born in Israel to Bulgarian and Iraqi parents, requested medical advice 2 years previously because of periodic pain in his left heel. He was generally in good health, and no special details were available from history. The pain was not related to any type of effort, there was no history of former trauma and no family history of any disease. Physical examination revealed

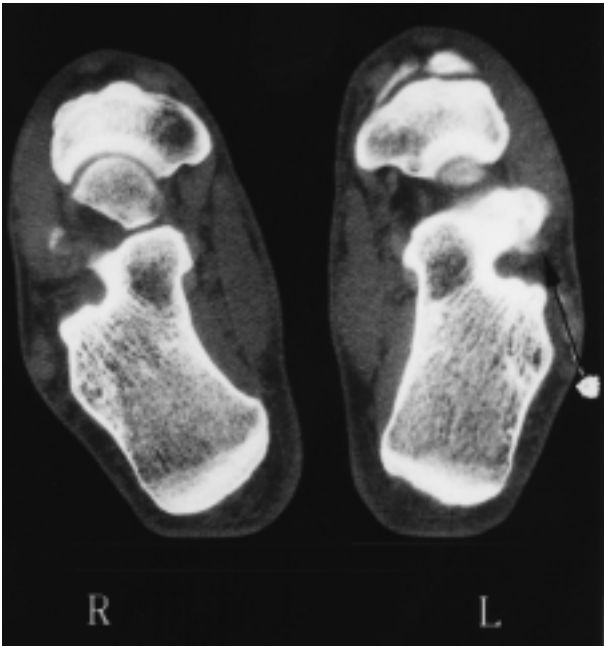
---

Department of Orthopedic Surgery, The Chaim Sheba Medical Center, Tel Hashomer, affiliated with the Sackler School of Medicine, Tel Aviv University, Israel.

Correspondence and reprints : M. Salai, Dept. of Orthopedic Surgery, The Chaim Sheba Medical Center, 52621 Tel Hashomer, Israel.

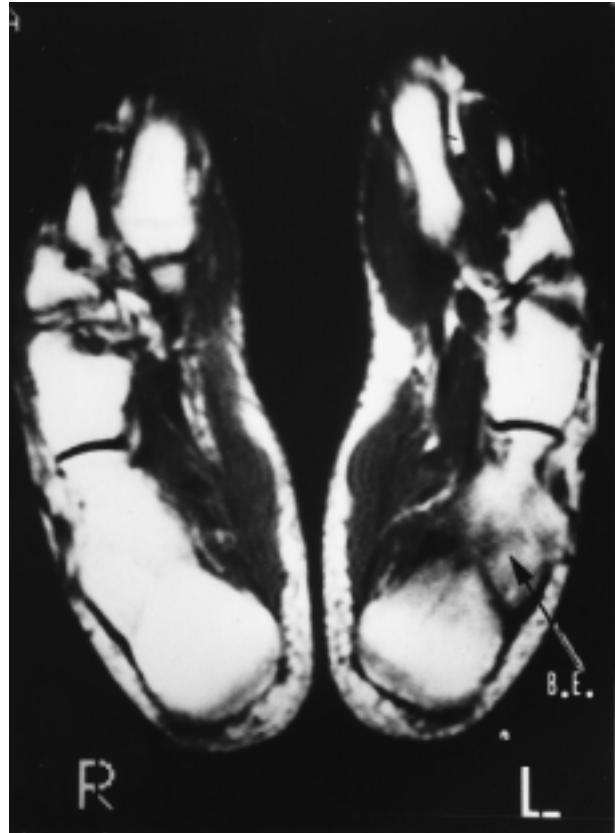


**Fig. 1.** — Tc-99 bone scan shows increased uptake in the posterior subtalar joint, especially on the posterior calcaneal facet.



**Fig. 2.** — CT shows a subchondral cyst on the posterior facet (arrow).

only local tenderness over the heel and mild local swelling. He was initially diagnosed as having Achilles tendinitis and was treated with nonsteroidal anti-inflammatory drugs, but with no improvement. Routine blood tests were normal. X-ray of the ankle and foot was normal. Bone scan with Tc-99 showed increased uptake in the posterior subtalar joint, especially on the calcaneal poste-



**Fig. 3.** — MRI shows a subchondral cyst on the posterior calcaneal facet with diffuse edema of the adjacent bone.

rior facet (fig. 1). Computer tomography (CT) examination performed subsequently revealed a subchondral cyst on the posterior facet (fig. 2). Magnetic resonance imaging (MRI) confirmed the diagnosis of the subchondral cyst on the calcaneal posterior facet, with edema of the adjacent bone (fig. 3). A CT-guided biopsy was carried out and a sample taken from the lesion. Histopathologic examination revealed nonspecific inflammatory changes of the cyst and the adjacent bone.

The pain and complaints spontaneously subsided after elimination of sports activities. A few months after biopsy the patient was admitted to the emergency room on three occasions ; twice for fever and chest pain and on the third occasion for abdominal pain and signs of peritoneal irritation.

Again, family history of any type of periodic attacks, either arthritic or abdominal, or chest pain,

was negative. Despite the negative family history and atypical presenting symptom of subtalar arthritis, the periodic pattern of the attacks raised the suspicion of FMF. Genetic examination revealed the 694/726 genetic variant, and confirmed the diagnosis of FMF.

Daily treatment with oral colchicine, 1 mg/day, was initiated with complete resolution of all complaints, including those of the left foot and ankle, and the patient resumed full physical activity.

## DISCUSSION

Familial Mediterranean fever is an autosomal recessive disease affecting mainly people of Mediterranean origin. The disease affects mostly young people, even in childhood, is common in non-Ashkenazi Jews, but can also be found in Palestinians, Arabs, and those of Turkish origin, especially Armenians, and even in Japan (12).

The earliest description of the disease by Janeway and Mosenthal in 1908 was of an unusual syndrome characterized by recurrent abdominal pain and vomiting. The disease was established as a clinical entity by Siegal in 1945 (10).

The prevalence of the disease, which is common in the Mediterranean area, occurs in up to 1/2600 births in Jordan, with a gene prevalence of 1/50 (8) and a carrier rate of 1/10 in North African Jews (11), and 1/12 in Iraqi Jews (7). Male prevalence is 60%. The age range is between 5 and 15 years, but it may also begin in infancy (8), and even at the age of 50. The disease is characterized by recurrent attacks of fever and some form of serositis, peritonitis, pleuritis or synovitis (4). Almost without exception, the symptoms and complaints are self-limiting, temporary, restricted to 72 hours and leave no direct residual. The only two exceptions are amyloidosis, which is the severe complication of the disease occurring in 1.7% to 60% of cases, which may lead to chronic renal failure and even death. Another exception is arthritis, especially in the hip joint, which may cause chronic changes and progress to severe osteoarthritis and joint destruction. Apart from fever, the most common symptom is abdominal pain, which appeared in 93% (3) to 82% (8) of patients, and was the presenting symp-

tom in about 50% of the cases (1, 8). Pleuritis occurred in 30% (1, 8) to 40% (3) of the patients. Arthritis appeared as a presenting symptom in about 25% (1, 3, 8).

Arthritis in FMF is usually acute, is only active for a short duration, usually lasting less than 1 week, and is self-limiting. The frequency of the attacks is unpredictable (3). There is a great deal of extrapolation concerning preceding factors that may induce attacks, among them excessive exertion, prolonged standing (11), significant trauma, stress, fat-rich diet, tuberculin injections, and more, but none of these have been proven.

When arthritis was the presenting symptom, it usually appeared before 12 years of age, and the children were diagnosed as suffering from juvenile rheumatoid arthritis.

Many studies support the efficacy of the prophylactic intake of colchicine, not only in reduction of frequency and intensity of attacks, but also by reducing the chances of amyloidosis, thereby curtailing the complication rates of chronic renal failure.

The difficulty of diagnosis is typical, as it was in our patient, i.e., young, with atypical subtalar arthritis as a presenting symptom and without any previous personal or family history of the disease. Heller *et al.* provided certain criteria for the diagnosis of FMF : 1) short attacks of fever recurring in varying intervals ; 2) painful sensation in the abdomen, chest, joints or skin accompanying the fever ; 3) absence of any cause or pathological finding capable of explaining the clinical picture.

The MEFV gene found to be responsible for FMF, located on the short arm of chromosome 16p, composed of 10 exons and an encoded 781 amino acid protein, was initially discovered by Pras *et al.* (5). The gene was first recognized in non-Ashkenazi Jewish families, and later was confirmed in all the major affected ethnic groups. Some variants of the gene, i.e., M694V and V726A, were also recognized, and it was suggested that the phenotypic variations in FMF may be due to the variance between these mutations and their combination. The M694V variant is very common in the population with the highest incidence for amyloidosis, especially North African Jews. The V726A variant is more common in the population where

amyloidosis is rare, especially in Iraqi and Ashkenazi Jews, Druse and Armenians. The M694V homozygote causes a more severe disease which includes earlier age of onset, more frequent and severe attacks and the need for higher amounts of colchicine to control the disease (2, 6). The disease in V726A carriers (homozygote or heterozygote with M694V) is considered by all parameters to be less severe, and these carriers do not usually have amyloidosis (2, 6). As mentioned previously, our patient had M694V/V726A genes, which confirmed the diagnosis of FMF.

The arthritis in FMF is typically acute, self-limited, temporary, usually exists for less than 72 hours and has no residual damage. The clinical manifestations are similar to any severe arthritis with local fever, tenderness, redness and swelling with a high count of polymorphonuclear cells in the articular fluid (even above 100,000 cells/mm<sup>3</sup>). Between attacks the patient is asymptomatic. The main affected areas are the large joints of the lower limb, knee, hip, and ankles initially in that order. It was also reported to occur in the shoulder (3), elbow, sacroiliac joint and the temporomandibular joint, toes, sternoclavicular joint, wrist and metatarsophalangeal joints.

No case of subtalar arthritis in FMF has been reported previously, and especially as a presenting symptom. Until recently, when the FMF gene was identified, the diagnosis of FMF was extremely complicated, especially in atypical cases such as ours. Many underwent unnecessary surgery due to suspected intra-abdominal "catastrophe", mostly exploratory laparotomy (1, 8).

## REFERENCES

1. Barakat M. H., Karnik A. M., Majeed H. W. A., El-Sobki N. I., Fenech F. F. Familial mediterranean fever (recurrent hereditary polyserositis) in Arabs — a study of 175 patients and review of the literature. *Quart. J. Med.*, 1986, 233, 837-847.
2. Brik R., Shinawi M., Kepten I., Berant M., Gershoni-Baruch R. Familial Mediterranean fever: clinical and genetic characterization in a mixed pediatric population of Jewish and Arab patients. *Pediatrics*, 1999, 103, e70.
3. Garcia-Gonzalez A., Weisman M.H. The arthritis of familial Mediterranean fever. *Sem. Arthritis Rheum.*, 1992, 22, 139-150.

4. Kaushansky K., Finerman G. A. M., Schwabe A. D. Chronic destructive arthritis in familial Mediterranean fever: The predominance of hip involvement and its management. *Clin. Orthop.* 1981, 155, 156-161.
5. Pras E., Aksentjevich I., Gruberg L., Balow J. E., Jr., Prosen L., Dean M., Steinberg A. D., Pras M., Kastner D. L. Mapping of a gene causing familial Mediterranean fever to the short arm of chromosome 16. *N. Engl. J. Med.*, 1992, 326, 1509-1513.
6. Pras E., Livnea A., Bellow J. E., Kastner D. L., Pras M., Langevitz P. Clinical differences between North African and Iraqi Jews with familial Mediterranean fever. *Am. J. Med. Genet.*, 1998, 75, 216.
7. Pras M., Bronshpigel N., Zemer D., Gafni J. Variable incidence of amyloidosis in familial Mediterranean fever among different ethnic groups. *Johns Hopkins Med. J.*, 1982, 150, 22-26.
8. Rawashdeh M. O., Majeed H. A. Familial Mediterranean fever in Arab children: The high prevalence and gene frequency. *Eur. J. Pediatr.*, 1996, 155, 540-544.
9. Salai M., Zemmer D., Segal E., Corat A., Heyman Z., Davidson B., Langevitz P., Livneh A. Chronic massive knee effusion in familial Mediterranean fever. *Semin. Arthr. Rheum.*, 1997, 3, 1-5.
10. Siegal S. Benign paroxysmal peritonitis. *Ann. Intern. Med.*, 1945, 23, 1-21.
11. Sohar E., Gafni J., Pras M., Heller H. Familial Mediterranean fever. A survey of 470 cases and review of the literature. *Am. J. Med.*, 1967, 43, 227-253.
12. Takahashi M., Ebe T., Kohara T., Inagaki M., Isonuma H., Hibiya I., Mori T., Watanabe K., Ikemoto H. Periodic fever compatible with familial Mediterranean fever. *Intern. Med.*, 1992, 31, 893-898.

## SAMENVATTING

I. DUDKIEWICZ, A. CHECHIK, A. BLANKSTEIN, M. SALAI. *Arthritis van het distale spronggewricht als deelsymptoom van familiale mediterraneane koorts.*

Familiale mediterraneane koorts is een recessief erfelijke aandoening die vooral bewoners van het Middellandse zeegebied treft.

Het ziekteverloop is acuut, gekenmerkt door spontaan verdwijnende hoge koortsoptosten met verschijnselen van peritonitis, pleuritis, en arthritis. Soms treedt een gelocaliseerde rash op in het enkelgebied suggestief voor erysipelas. Pericarditis en massieve kniehydrops zijn eveneens als zeldzame deelsymptomen beschreven. Identificatie van het specifieke gen voor FMF maakt de diagnose nu zeker.

Wij beschrijven een geval waarbij subtalaire arthritis een deelsymptoom was. Er was geen voorafgaande van FMF

noch bij de patiënt, noch bij de familie, maar de aanwezigheid van het gen variant 694/726 was diagnostisch voor FMF.

Eén mg colchicine per dag deed de symptomen volledig verdwijnen.

### RÉSUMÉ

*I. DUDKIEWICZ, A. CHECHIK, A. BLANKSTEIN, M. SALAI. Arthrite sous-astragaliennne comme symptôme inaugural d'une fièvre méditerranéenne familiale : présentation d'un cas et revue de la littérature.*

La fièvre méditerranéenne familiale est une affection autosomique récessive qui affecte surtout des sujets d'origine méditerranéenne. Le tableau clinique primaire de cette maladie est caractérisé par des épisodes péri-

diques d'hyperthermie importante, à résolution spontanée, accompagnés par une péritonite, une pleurite ou une arthrite et parfois par un exanthème typique au niveau des chevilles qui peut simuler une érysipèle. Des signes inauguraux tels qu'une péricardite ou un épanchement liquidien important au niveau du genou ont été rapportés plus rarement dans la littérature. Le diagnostic est récemment devenu beaucoup plus sûr grâce à l'identification d'un gène responsable de cette affection. Les auteurs rapportent le cas d'un patient sans histoire personnelle ou familiale de fièvre méditerranéenne familiale et chez qui le premier signe clinique a été une arthrite sous-astragaliennne. La mise au point génétique a montré une variante génétique 694/726 qui a confirmé le diagnostic. L'administration quotidienne de colchicine à la dose d'un milligramme/jour a fait disparaître complètement les symptômes.