



Acute exertional compartment syndrome of the superficial posterior compartment of the leg

Koppa N. R. SRIKANTH, Mark CHONG, Keith PORTER

From Royal Oldham Hospital, Manchester, United Kingdom and the University Hospital, Birmingham, United Kingdom

Acute exertional compartment syndrome of the superficial posterior compartment of the leg secondary to minor soft tissue injury is rare. This case series highlights the risk of misdiagnosis as deep venous thrombosis, followed by inadvertent anticoagulation. The delay in management did fortunately not lead to catastrophic consequences. Clinicians must not dismiss the possibility of an acute exertional compartment syndrome in the absence of direct trauma or after minor closed soft tissue injury.

Keywords : acute compartment syndrome ; delayed presentation ; superficial posterior compartment ; acute exertional ; anticoagulation.

INTRODUCTION

Acute exertional compartment syndrome of the superficial posterior compartment of the calf, i.e. the gastrocnemius/soleus muscle complex, is rare after minor soft tissue injury (1, 8). The common mechanism involves a relatively minor trauma causing muscle injury, haematoma formation and subsequent increased intra-compartmental pressure (1, 10).

This paper presents three cases of acute exertional compartment syndrome with 'delayed' presentation, delay in diagnosis and delivery of treatment.

CASE REPORTS

Case 1

A fit previously healthy 50-year-old solicitor developed pain in the middle of the left calf whilst walking for a train. There was no history of trauma. He had been on a long haul flight three months before.

Due to increasing pain, swelling, difficulty in walking and numbness in the sole of his foot, he attended an accident and emergency department a few hours later. Clinically he had calf tenderness. There was no recorded neurovascular deficit. A Duplex ultrasound scan showed no evidence of a

■ Koppa N. R. Srikanth, MBBS, D'Orth, MRCSI, Registrar, Trauma and Orthopaedics.

Royal Oldham Hospital, Manchester, United Kingdom.

■ Mark Chong, MBBS, BSc, MRCS (Eng), Senior House Officer, Trauma and Orthopaedics.

University Hospital Birmingham, West Midlands, United Kingdom.

■ Keith Porter, MBBS, FRCS (Eng), FRCS (Ed), FIMC, RCS (Ed), Consultant Trauma and Orthopaedic Surgeon.

University Hospital Birmingham, West Midlands, United Kingdom.

Correspondence : Mr Koppa N. Srikanth, 8 Cambrian Drive, Royton, Greater Manchester OL2 5EU, United Kingdom.

E-mail : knsrikanth@hotmail.com.

© 2006, Acta Orthopædica Belgica.

deep venous thrombosis (DVT) but demonstrated an intramuscular haematoma deep to the gastrocnemius muscle. He was reassured and discharged with analgesics.

He presented the following day with increasing severity of pain and a calf 25% greater in circumference compared with the other calf. He had a "burning" pain in the upper calf and clinically altered sensation in the back of the calf. Foot pulses were normal. The clinical diagnosis of compartment syndrome was confirmed with a compartment pressure reading of 80 mmHg (Stryker Instruments, Kalamazoo, Michigan).

He underwent fasciotomy, during which the soleus muscle was found to be dusky and oedematous and to present a tear in the proximal part. The wound was left open and dressed and subsequently closed under general anaesthetic at 72 hours. At discharge, he continued to complain of numbness in the area of altered skin sensation.

Case 2

A fit, healthy 27-year-old electrician presented to the accident and emergency department with swelling and pain of the calf of sudden onset, developed after jogging. He had suffered a low-grade discomfort in the calf for approximately a week preceding this.

Clinically the left calf was swollen, with a 5cm increase in circumference compared to the right calf. Sensation and circulation were normal. The clinical diagnosis was deep venous thrombosis (DVT) and the patient was prescribed low molecular weight heparin.

Some hours later he again presented, barely able to weight bear. He had an extensive swelling of the calf. Pain on passive dorsiflexion of the ankle was present and there was associated numbness on the posterior aspect of the calf. Baseline blood tests including a clotting screen were normal. A Doppler ultrasound scan revealed a 10cm by 4cm haematoma on the medial aspect of calf. There was no evidence of a DVT (fig 1).

An emergency fasciotomy was performed and a tear was identified at the proximal end of the soleus muscle with some blood in the compartment.

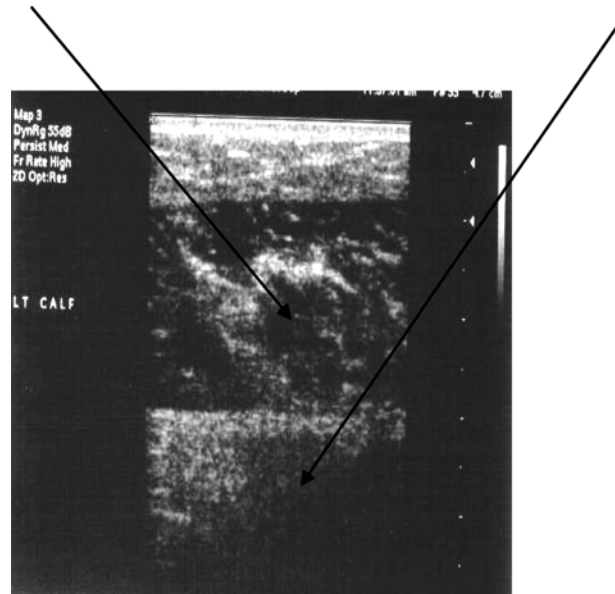


Fig. 1. — Doppler ultrasound scan of left calf depicting a 10 × 4 cm haematoma in the medial aspect of the gastrocnemius muscle.

Necrotic muscle was debrided and the wound was left open. Following wound inspection, closure was undertaken on the fourth postoperative day. The patient made a good recovery with no residual neurological deficit.

Case 3

An 18-year-old previously fit and healthy male presented to an accident and emergency department with pain in his left calf of sudden onset after a long walk. There was no associated history of trauma and no relevant past history.

Examination revealed a tense, painful calf with a 4cm increase in circumference. There was no neurovascular deficit. Baseline blood tests including D-dimers were normal. A diagnosis of DVT was made in the casualty department; the patient was prescribed low molecular weight heparin.

He represented at casualty with increasing severity of pain, a stony hard calf and pain on passively dorsiflexing the ankle. The compartment pressure was 70mm Hg (Stryker Instruments). The creatine-kinase level was 900 units.

An immediate fasciotomy was performed revealing a tear in the proximal part of the gastrocnemius muscle. The wound was left open and subsequently closed on the fourth postoperative day. He made a good recovery with no neurological deficit.

DISCUSSION

Acute exertional compartment syndrome is rare and involvement of the superficial posterior compartment of the calf is even rarer (8). Most typically it presents as a chronic recurring pain, induced by exercise, commonly seen in athletes and young military recruits (1, 2, 6) but it can also occur in non-athlete individuals (8).

The clinical diagnosis is less obvious in the posterior compartment than in other muscle compartments in the lower limb, because, being a larger compartment, it is able to withstand a greater increase in pressure before muscle ischaemia develops (6).

The Stryker device is simple enough to operate, and even physicians who use it only occasionally can reasonably expect to get accurate results. Normal compartment pressures should be less than 10 mm Hg, but may rise a few millimetres with muscle contraction. The difference between the diastolic blood pressure and compartment pressure is more useful, and a compartment pressure within 30 mm Hg of the diastolic blood pressure should be considered indicative of an acute compartment syndrome. Diagnostic for chronic exertional compartment syndrome are a resting pressure greater than 20 mm Hg is, or an exertional pressure greater than 30 mm Hg, or a pressure of 25 mm Hg or higher 5 minutes after stopping exercise.

Fasciotomy of the anterior compartment has a better outcome than fasciotomy of the deep posterior compartment. In one study 25 of the 26 patients who underwent fasciotomy of the anterior compartment reported excellent results (96%), while the 12 patients (20 limbs) who underwent fasciotomy of the deep posterior compartment reported varied results: 13 of 20 limbs (65%) had satisfactory results (5 excellent and 8 good) and 7 (35%) had unsatisfactory results (4 fair and 3 poor) (5). Furthermore, the rehabilitation phase

was prolonged for patients who underwent deep posterior compartment fasciotomy compared with those who had anterior compartment fasciotomy (16 months versus 7 months, respectively) (7, 9). Other studies have mirrored this outcome, with fasciotomy of the deep posterior compartment being significantly less effective in providing prolonged symptom relief. Why treatment efficacy is different in these two compartments is unclear.

The differential diagnosis of acute calf pain includes deep venous thrombosis, stress fracture of tibia or fibula, tenosynovitis, periostitis, vascular and neurological entrapment syndromes, claudication, infection, myopathy (to include thyroid myopathy), tumour, medial tibial stress syndrome, ruptured Baker cyst, muscle injuries including tennis leg and compartment syndrome.

DVT can be confused with compartment syndrome as happened in cases 2 and 3, mostly when trauma is not the cause. Case 1 details a minor soft tissue injury. DVT was excluded by Duplex scanning and acute exertional compartment syndrome developed later. Case 2 had calf pain for a week's time and the unaccustomed exercise tipped him over from chronic to acute exertional compartment syndrome. In case 2 and 3 a presumptive diagnosis of DVT was made and anticoagulation prescribed. Acute compartment syndrome followed possibly due to additional bleeding.

Collectively these three cases present the consequences of a diagnostic dilemma, delay in diagnosis leading to muscle necrosis and neurological consequences particularly in case 1 that was left with residual numbness. More sinister complications including rhabdomyolysis and acute renal failure did not occur. Such delayed treatment keeps recurring despite earlier reports, illustrating the old saying of history repeating itself (3, 4). These cases illustrate the necessity for careful observation of non-trauma related acute leg pain appearing even at the beginning of strenuous exercise.

The pathophysiology of exertional compartment syndrome is poorly understood. It is believed that increased muscle bulk after exercise and a tight compartment are responsible for the chronic exertional variety, but muscle herniation and muscle tear could be other possible mechanisms, and can

lead to acute presentation. This should be differentiated from conditions like "Tennis leg" which is more common after 40 years of age, where a superficial posterior compartment muscle ruptures like in our case but this rarely leads to compartment syndrome and is usually treated conservatively.

It is important to recognise the possibility of a very acute onset of exertional compartment syndrome that does not subside with rest. Only early diagnosis and fasciotomy can prevent severe complications of an acute exertional compartment syndrome. Despite the late presentation, surgical decompression is essential (6).

Duplex ultrasonography should be undertaken as a first line investigation to confirm the clinically presumed diagnosis of a DVT prior to anticoagulation. This would have prevented inadvertent anticoagulation in case 2 and 3. In patients with suspected DVT in whom inadvertent anticoagulation was administered, the clinician should be aware of the risk of worsening a chronic exertional compartment syndrome to an acute compartment syndrome.

A high index of suspicion, adequate utilisation of investigations like Doppler and compartment pressure monitoring allows prompt diagnosis. Urgent fasciotomy will enable a full recovery without complications.

REFERENCES

1. **Allen MJ, Barnes MR.** Unusual cause of acute superficial posterior compartment syndrome. *Injury* 1992 ; 23 : 202-203.
2. **Green JE, Crowley B.** Acute exertional compartment syndrome in an athlete. *Br J Plast Surg* 2001 ; 54 : 265-267.
3. **McHale KM, Prahinski JR.** Acute exertional compartment syndrome occurring after performance of the army physical fitness test. *Orthop Rev* 1994 ; 23 : 749-753.
4. **Mubarak SJ, Owen CA, Garfin S, Hargens AR.** Acute exertional superficial posterior compartment syndrome. *Am J Sports Med* 1978 ; 6 : 287-290.
5. **Schepesis AA, Martini D, Corbett M.** Surgical management of exertional compartment syndrome of the lower leg. Long-term follow-up. *Am J Sports Med* 1993 ; 21 : 811-817.
6. **Shaw CJ, Spencer JD.** Late management of compartment syndrome. *Injury* 1995 ; 2 : 633-635.
7. **Swain R, Ross D.** Lower extremity compartment syndrome : When to suspect acute or chronic pressure build-up. *Postgrad med* 1999 ; 105 : 159-162, 165, 168.
8. **Thennavan A, Funk L, Volans AP.** Acute compartment syndrome after muscle rupture in non-athlete. *J Accid Emerg Med* 1999 ; 16 : 377-378.
9. **Wallenstein R.** Results of fasciotomy in patients with medial tibial syndrome or chronic anterior-compartment syndrome. *J Bone Joint Surg* 1983 ; 65-A : 1252-1255.
10. **Williams P, Shenolikar A, Roberts RC, Davies RM.** Acute non-traumatic compartment syndrome related to soft tissue injury. *Injury* 1996 ; 2 : 507-508.