



The effect of local administration of phenytoin on fracture healing : An experimental study

Manoj MATHEW, Mandeep S. DHILLON, Onkar N. NAGI, Ramesh K. SEN, Ritambhra NADA

From the Postgraduate Institute of Medical Education and Research, Chandigarh, India

The antiepileptic drug phenytoin (Diphenylhydantoin) has been documented to have a beneficial effect on wound healing ; its effect on fracture healing, however is still unclear. In an attempt to evaluate any potential benefits phenytoin may have on fracture healing, a prospective study was undertaken combining histology, histomorphometry and radiology, in which the effects of locally administered phenytoin were analysed.

Twenty-four Wistar strain rats of 8-9 months age were assigned into two groups of 12 each (matched for age, sex and weight). In the study group, phenytoin 20 mg/kg was administered through a 24 gauge needle directly on to the fracture site every 72 hours, while in the control group an equivalent volume of normal saline was administered at similar intervals. At 28 days radiographic and histological analysis was done, the scoring for which did not show any statistical difference between the control and test animals. Histomorphometric analysis of the callus however, showed that the total periosteal callus on either side of the central bridging callus was mineralised to a greater extent in the phenytoin group animals as compared to the control group animals ($p = 0.011$).

After analysing our data, we concluded that phenytoin does have an influence in fracture healing, albeit small, which is primarily on the hard callus region. The hard callus region is the high oxygen tension region and the first region to differentiate. It appears that the effect of phenytoin is probably exerted at the early mesenchymal differentiation stage. However our preliminary work shows that the effect is small and it is not justifiable at this stage to advocate the use of phenytoin clinically to augment fracture healing.

Keywords : phenytoin ; diphenylhydantoin ; callus ; fracture healing ; histomorphometry.

INTRODUCTION

Attempts at aiding fracture healing using medical agents are evolving. The antiepileptic drug phenytoin has been documented in the past to have a stimulatory effect on granulation tissue formation and wound healing (10). Experimental work into such a potential benefit of this drug was partly inspired from the observation of altered collagen metabolism and increased angiogenesis in the gums resulting in gum hypertrophy following its long term administration (3).

-
- Manoj Mathew, MS (Ortho), Senior Resident.
 - Mandeep S. Dhillon, MS (Ortho), MNAMS, Professor.
 - Onkar N. Nagi, MS (Ortho), MSc (Oxon), FAMS, Emeritus Professor.
 - Ramesh K. Sen, MS (Ortho), DNB, Additional Professor.
Department of Orthopaedic Surgery, Postgraduate Institute of Medical Education and Research, Chandigarh, India.
 - Ritambhra Nada, MD (Path), Additional Professor.
Department of Histopathology, Postgraduate Institute of Medical Education and Research, Chandigarh, India.
- Correspondence : Dr Manoj Mathew, Department of Orthopaedics, PGIMER, Chandigarh 160012, India.
E-mail : drdhillon@gmail.com ; drmanoj4u@yahoo.com.
© 2006, Acta Orthopædica Belgica.
-

Since wound healing and fracture healing do have several common denominators including angiogenesis, collagen synthesis and the release of several chemical mediators, it appeared logical that the effect phenytoin had in wound healing could probably extend over into fracture healing as well. There are very few studies that have investigated the effect of phenytoin in fracture healing. One study reports an inhibitory effect of phenytoin on bone healing (6), while two other studies have reported an augmenting capacity of phenytoin in fracture healing (4, 11). In an attempt to clarify if phenytoin had any beneficial effects on fracture healing, we attempted a combination of histology, histomorphometry and radiology to analyse the effects of locally administered phenytoin on fracture healing, in an experimental fracture model.

MATERIALS AND METHODS

Study design

The study was a single level blocked randomised controlled trial. Twenty-four Wistar strain rats (*Rattus norvegicus albinus*) weighing 200-400 g, procured from the Central Animal House of our institution, which had been screened for natural diseases, were used. They were divided into two groups of 12 each, who had been matched for age, sex and weight. Any animal lost mid way was replaced with another animal of same sex, weight and age. All animals were handled in accordance with the guidelines laid out in the Guide for the Care and Use of Laboratory Animals (2). The Institutional Animal Ethics Committee had approved the experimental work.

Surgical Procedure

The surgery was performed at the operation theatre at the Central Animal House, (Postgraduate Institute of Medical Education and Research, Chandigarh, India) under the supervision of the veterinarian in charge. The experimental animal was anaesthetised with Ketamine 40 mg/kg along with atropine, given through the intraperitoneal route, supplemented with local infiltration of lignocaine 10 mg/kg. An anterolateral approach was used to expose the middle third of the tibia. A clean osteotomy was made using a saw. The osteotomy was fixed using a 18 G hypodermic needle, which served as an intramedullary nailing device. The wound was closed using a single silk suture.

Ten doses of phenytoin (20 mg/kg) were administered at the fracture site in the experimental group animals. The first dose was introduced at the time of surgery and all subsequent doses were spaced at 72-hour intervals. The drug was delivered locally using a 1 ml syringe with a 24 G needle. The superficial situation of the tibia facilitated local drug delivery. This was ensured to be in the tissue planes as adjacent to the fracture site as possible by walking the needle along the tibia till the gap of the osteotomy was felt, in the initial phases (3 doses), and into a plane immediately overlying the maximal palpable prominence of the fracture callus in the later stages (latter 6 doses). The animals were euthanised at the end of 28 days by thiopental over dosage (Sleep-Away) technique.

Radiographic Study

Radiographs were taken in both antero-posterior and lateral planes with the fixation device *in situ* and union graded on a 6-scale union score as described by Sano *et al* (8); 0 : sharp or sclerotic line seen throughout ; 1 : sharp or sclerotic line in more than 75% of diameter ; 2 : a well-defined osteotomy line extending between 50 and 75% of the diameter in both projections ; 3 : same as 2 but in one projection only ; 4 : osteotomy faintly seen ; 5 : osteotomy not seen. The analysis was done by an investigator who had been blinded for the groups (fig 1).

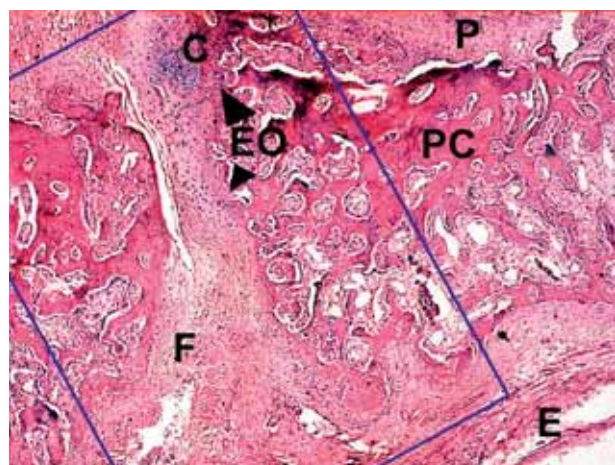


Fig. 1. — Lateral view radiographs, Mex1 and Mex14 are from the control group while Mex9 and Mex12 are from the Phenytoin group.

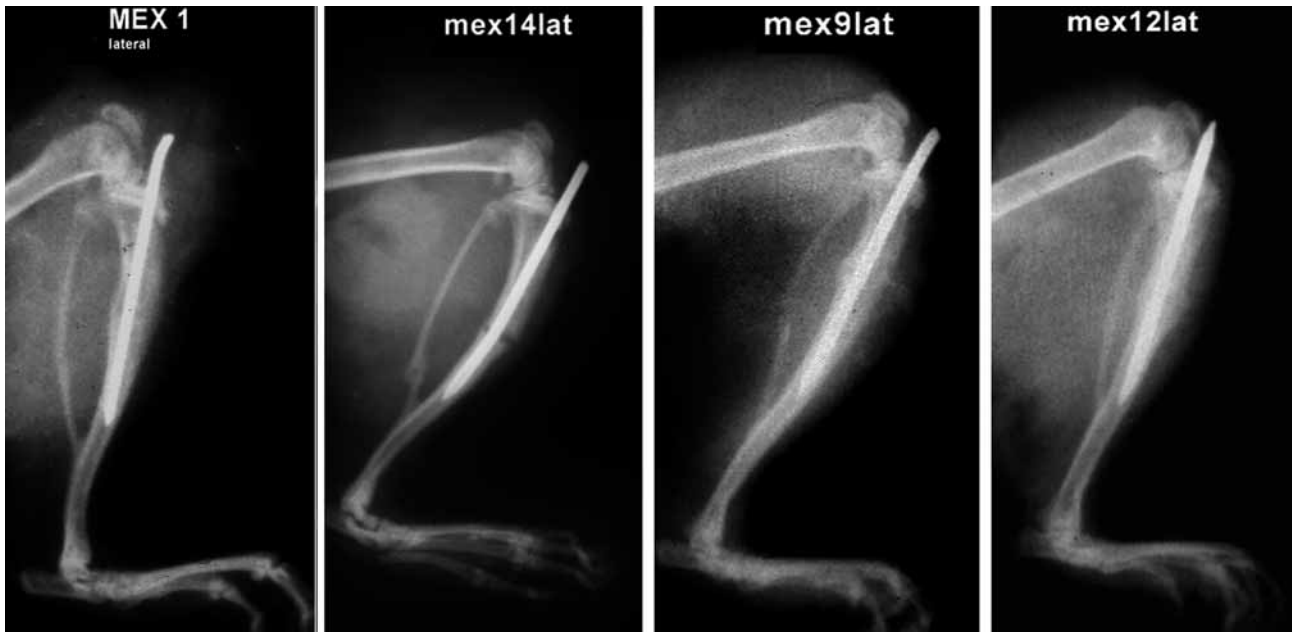


Fig. 2. — Low power photomicrograph ($\times 140$, Haematoxylin & Eosin) showing the analysed regions (specimen Mex1) C-cartilaginous islands, P- periosteum, E- endosteum F-fibrous tissue, EO - enchondral ossification front ; the area within the box is the primary area of interest.

Histology and histomorphometry

The right tibia was dissected out, fixed in 10% buffered formalin solution over 7 days and decalcified in an acidic medium (5% nitric acid with 0.5% urea). The specimens were sectioned sagittally and embedded in high melting point paraffin. A Leica 2125RJ microtome (Bensheim, Germany) was used to cut sections of 5-8 mm thickness. An investigator who had been blinded for the groups under study did all the evaluations on Haematoxylin and Eosin stained specimens (fig 2). The over-bridging callus was graded histologically by a 10 point grading scale as described by Huddleston *et al* (5) using a Leica DM RBE microscope (Wetzlar, Germany) ; grade 1 : fibrous union ; grade 2 : predominantly fibrous tissue with some cartilage ; grade 3 : equal amounts of fibrous tissue and cartilage ; grade 4 : all cartilage ; grade 5 : predominantly cartilage with some woven bone ; grade 6 : equal amounts of cartilage and woven bone ; grade 7 : predominantly woven bone with some cartilage ; grade 8 : entirely woven bone ; grade 9 : woven bone and some mature bone ; grade 10 : lamellar (mature) bone.

Gomori's one-step trichrome staining technique was used on decalcified specimens for histomorphometric

analysis. Histomorphometry was performed with a Leica DM RBE microscope (Wetzlar, Germany) mounted with a Sony RGB/3CCD camera (Sony Co. Tokyo, Japan) and interfaced with a Quantimet 600S image analysis system (Leica Cambridge Ltd., Cambridge, England). The bridging callus was analysed interactively for total area, fibrous area, cartilaginous area, bony area and mineralised part of the bony area, and the whole periosteal callus was assessed for mineralisation (fig 3).

Statistical analysis

Statistical analysis was performed under the null hypothesis that phenytoin exerted no effect on fracture healing. Median statistics were used in ordinal scales and non-parametric data was analysed using the Wilcoxon sign rank test. Continuous variables were compared using the two-sample t-test after appropriate tests of normality. Power analysis was done at 80% power assigning $\alpha < 0.05$ and $\beta < 0.2$ with $p < 0.05$. The NCSS2000/PASS2000 software (Kaysville, Utah, U.S.A.) was used to assist in statistical calculations.

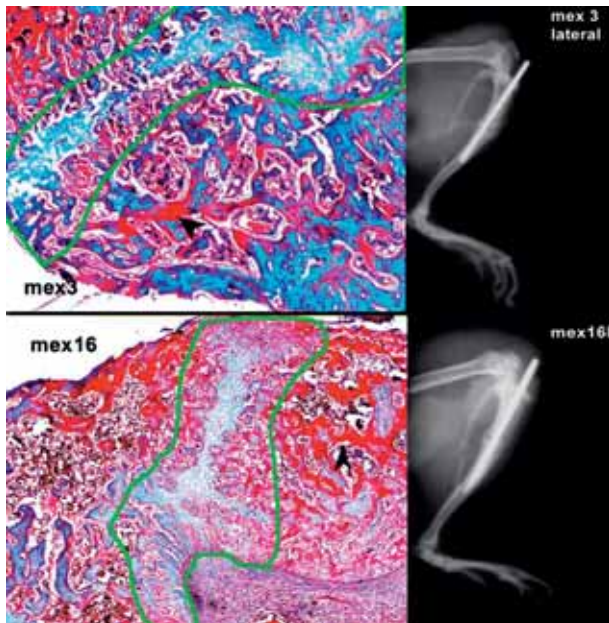


Fig. 3. — Low power photomicrograph ($\times 140$, Gomori's staining) along with lateral view radiographs of experimental animals Mex3 and Mex16 showing the areas of mineralisation (indicated by the arrow head). The green area outlines the bridging callus. The difference in mineralisation in the callus quantified on either side of this bridging callus showed statistical significance.

RESULTS

Radiographic analysis

The mean radiographic score in the phenytoin treated group was 3.08 as against a mean score of 2.58 in the controls (fig 1). The difference was not statistically significant. The medians in both groups were 3. Wilcoxon sign rank sum test for two tailed t-test yielded that the null hypothesis stood true.

Histological analysis

The part of the callus most consistently showing inter-specimen variation was the bridging callus centralised at the level of cortical defect and extending from the endosteal level to the periphery of the periosteal callus. There were three cases of fibrous union (ID No : Mex2, Mex6 and Mex7). All the remaining specimens were in various stages of

endochondral ossification. An advanced stage of bony (woven bone) union was noted in four animals (ID No : Mex3, Mex8, Mex13, Mex21). The median histological score in the phenytoin group was 6.5 as against a median score of 6 in the control group. The difference was not statistically significant (fig 2).

Histomorphometric analysis

When the whole periosteal callus excluding the central bridging part was assessed for mineralisation, it was found that a statistically significant difference existed in the proportion of mineralised part of the periosteal callus between the control and phenytoin groups (p value = 0.011), with the phenytoin group demonstrating a better mineralisation ratio (table I). Special mention should be made here regarding statistical outliers. The control animal ID No : Mex7 showed an abnormal amount of fibrous tissue in the sample. This animal along with two more control animals with a high fibrous content in the callus were removed as statistical outliers and two-sample t-test repeated to ensure that the observed difference in fracture healing had not been unduly over expressed by their presence. The difference in mineralisation of periosteal callus was still at statistically significant levels ($p = 0.041$).

Serum Phenytoin level

Blood samples collected at euthanasia were assessed for the level of phenytoin. None of the samples contained estimable levels of phenytoin, the minimum sensitivity of the HPCL system used (Waters HPCL system, Waters Associates, Milford, MA) for assay being $0.01 \mu\text{g/ml}$.

DISCUSSION

Phenytoin or diphenylhydantoin is a pharmacological agent that was developed as a non-sedative antiepileptic derivative of barbiturate (7). The toxic effect of phenytoin depends on the route of administration, the duration of exposure and the dosage. A particularly intriguing and interesting adverse effect, gingival hyperplasia has been reported to be

Table I. — Results of histomorphometry : Bone%, Cart% and Fib% is the percentage area occupied by bone, cartilage and fibrous tissue respectively in the central bridging callus ; %Min of TP callus is the percentage of the periosteal callus that is mineralised

CONTROL GROUP					PHENYTOIN GROUP				
ID No.	Bone%	Cart.%	Fib.%	%Min. of T.P. callus	ID No.	Bone%	Cart.%	Fib.%	%Min. of T.P. callus
Male control group					Male Phenytoin group				
Mex1	92.57	7.43	0	25.04	Mex9	65.16	19.38	15.46	41.44
Mex4	73.62	16.39	9.99	22.14	Mex16	44.52	55.48	0	43.57
Mex13	1.95	98.05	0	14.98	Mex19	53.2	17.6	29.19	39.49
Mex14	4.93	75.77	19.3	37.79	Mex20	64.92	35.08	0	22.12
Mex17	77.53	22.47	0	21.71	Mex22	53.52	34.62	11.86	32.43
Mex26	76.48	17.4	6.12	11.94	Mex25	52.23	47.77	0	18.62
Female control group					Female Phenytoin group				
Mex2	9.32	19.02	71.66	16.73	Mex10	93.63	4.28	2.09	30.21
Mex3	18.07	81.93	0	26.62	Mex12	92.9	7.1	0	28.27
Mex5	89.06	8.34	2.6	17.48	Mex21	85.23	3.28	11.49	19.81
Mex6	10.05	15.9	74.05	17.24	Mex23	71.74	25.63	2.64	16.36
Mex7	4.95	3.65	91.4	20.67	Mex24	46.85	27.46	25.69	38.05
Mex8	76.45	23.55	0	16.35	Mex27	10.84	89.16	0	29.52

due to its effect on collagen metabolism and this apparent stimulatory effect in connective tissue suggests an exciting possibility for use in wound healing (10).

Studies have demonstrated favourable results with topical application of phenytoin in the treatment of trophic ulceration in leprosy, venous stasis ulcers, decubitus ulcers, diabetic foot ulcers, ulcers of various aetiologies, large abscess cavities, burns, clean surgical wounds etc (9, 10). Biopsies of these phenytoin treated open wounds showed earlier appearance of mononuclear cells, eosinophils, fibroblasts, collagen deposition, neovascularisation, re-epithelialisation and decreased polymorphonuclear exudates, indicating that its influence on wound healing could be by inducing cell proliferation and the recruitment of cells to the area. Investigators have also concluded that systemic absorption after topical application of phenytoin is not significant (9, 10). Inflammation, chemotaxis, growth factor release, angiogenesis, collagen deposition, tissue organisation, and matrix remodelling are among the fundamental steps in fracture healing. It would be reasonable enough to expect

phenytoin, which influences these processes in wound healing to have a similar effect on fracture healing as well. However the possibility of phenytoin being a possible inhibitor of fracture healing cannot be ruled out in view of the fact that osteomalacia does occur with long-term systemic administration of phenytoin (1).

We could only find in the literature three studies on the effect of phenytoin in fracture healing. Mascres *et al* (6) studied the effect of systemically administered phenytoin on bone repair in maxillary and mandibular bony cavities in Sprague – Dawley rats and concluded that phenytoin delayed bony repair. The results in their study are difficult to be extrapolated to fracture union as the study was done in a bone cavity healing model and not a fracture-healing model. Frymoyer *et al* (4) had demonstrated accelerated bony union by systemically administered phenytoin in fibula fractures where the fracture healing was evaluated only on histological grounds. Of the three studies available only the study by Yang *et al* (11) had evaluated locally administered phenytoin. The investigators had assessed fracture healing with callus weighing,

radiography and histology. This method of fracture callus quantity assessment overlooks the fact that abundant fibrous callus may form even in the total absence of bony union making this criterion of assessing fracture union inherently contain a high probability of type-1 error. In our study this factor had been looked into and we compared callus quality using histomorphometry. On analysing the results the following inferences were arrived at :

1. There was a trend in fracture healing promotion in the phenytoin group animals as indicated by radiological and histological score. This difference could not attain statistical significance at current sample size levels and would manifest at $\alpha < 0.05$ and $\beta < 0.2$ at a sample size > 70 (at least 35 in each group)
2. A statistically significant difference in mineralisation of total periosteal callus was noted ($p = 0.011$).

We have drawn the following postulates to explain the interesting observation that the peripheral callus on either side of the central bridging callus in the phenytoin group had a better amount of mineralised bone content as compared to the central bridging callus :

1. The effect exerted by phenytoin in fracture healing is probably in the early inflammatory stage during mesenchymal differentiation. At this early stage most activity is in the immediate subperiosteal area while the low oxygen tension central part of the callus differentiates into cartilage and woven bone at a later stage.
2. Differences in phase of cell cycle, cell type and cell density between the cell pools of the central callus and peripheral callus could influence the difference in response. Inconsistent outcomes have been reported in the past during in vitro studies of phenytoin in tissue healing. These variable responses were attributed to the property that drug effects were dependent upon cell type, cell density and phase of cell cycle (10).
3. Phenytoin has low aqueous solubility (7, 10). This would have influenced drug absorption at the site of delivery. The tendency of phenytoin to precipitate locally (7) could have contributed to decreased drug diffusion across the callus.

Fracture healing unlike superficial wound healing is a long drawn process and in view of the known adverse effects of long term systemic administration of phenytoin we had excluded this route of drug administration from our study design.

There are a few shortcomings to our study. The study was a single level study and time effect had not been analysed. This study was however intended primarily to establish the effect whatsoever locally administered phenytoin had on fracture healing, with a limited number of experimental animals. The single level design was chosen to achieve maximum sample allocation per group with a limited amount of animals being sacrificed. Mechanical testing could not be done due to unavailability of appropriate equipment.

CONCLUSION

Summarising the inference drawn at this stage, there appears to be a positive influence of phenytoin in fracture healing in the whole periosteal callus, especially in the already hypervascular zones like the subperiosteal location. The effect however is small and it is not justifiable at this stage to advocate the use of phenytoin clinically for augmenting fracture healing.

REFERENCES

1. **Buckwalter JA, Einhorn TA, Marsh JC.** Bone and Joint healing. In : Bucholz RW, Heckman JD (eds). *Rockwood and Green's Fractures in Adults*. 5th ed. Lippincott Williams and Wilkins, Philadelphia 2001, pp 245-272.
2. **Committee on Care and Use of Laboratory Animals of the Institute of Laboratory Animal Resources, National Research Council.** Guide for the care and use of laboratory animals. Washington, DC : National Academy Press ; 1996.
3. **DaCosta ML, Regan MC, al Sader M et al.** Diphenylhydantoin sodium promotes early and marked angiogenesis and results in increased collagen deposition and tensile strength in healing wounds. *Surgery* 1998 ; 123 : 287-293.
4. **Frymoyer JW.** Fracture healing in rats treated with diphenylhydantoin. *J Trauma* 1976 ; 16 : 368-370.
5. **Huddleston PM, Steckelberg JM, Hanssen AD et al.** Ciprofloxacin inhibition of experimental fracture healing. *J Bone Joint Surg* 2000 ; 82-A : 161-173.

6. **Mascres C, Marchand JF.** The influence of sodium diphenylhydantionate on bone healing in the rat. *J Biol Buccale* 1983 ; 11 : 137-152.
7. **McNamara JO.** Drugs acting on the central nervous system. In : Hardman JG, Limbrid LE, Gilman AG (eds). *Goodman and Gilman's The Pharmacological Basis of Therapeutics*. 20th ed. New York : McGraw Hill, 2001, vol 1, pp 521-548.
8. **Sano H, Unthoff HK, Backman DS, Yeadong A.** Correlation of radiographic measurements with biomechanical test results. *Clin Orthop* 1999 ; 368 : 271-278.
9. **Smith BH, Moore M, Jain K.** The first international conference on the uses of phenytoin in dermatology. *Int J Dermatol* 1988 ; 27 : 528-530.
10. **Talas G, Brown RA, McGrouther DA.** Role of phenytoin in wound healing-A wound pharmacology perspective. *Biochem Pharmacol* 1999 ; 57 : 1085-1094.
11. **Yang T, Meng Z, Yang Z.** The effect of phenytoin in healing of fractures of rabbits. *Zhongguo Xiu Fu Chong Jian Wai Ke Za Zhi* 1997 ; 11 : 149-152.