



## Posterior lumbar interbody fusion (PLIF) with cages and local bone graft in the treatment of spinal stenosis

Hans TROUILLIER, Christof BIRKENMAIER, Alexander RAUCH, Christoph WEILER,  
Thomas KAUSCHKE, Hans Jürgen REFIIOR

*From Franziskus Hospital Bielefeld, Germany, and Orthopaedic Clinic and Institute of Pathology,  
Ludwig - Maximilian University Munich, Germany*

Posterior lumbar interbody fusion (PLIF) implants are increasingly being used for 360° fusion after decompression of lumbar spinal stenosis combined with degenerative instability. Both titanium and PEEK (PolyEtherEtherKetone) implants are commonly used. Assessing the clinical and radiological results as well as typical complications, such as migration of the cages, is important. In addition, questions such as which radiological parameters can be used to assess successful fusion, and whether the exclusive use of local bone graft is sufficient, are frequently debated.

We prospectively evaluated 30 patients after PLIF instrumentation for degenerative lumbar spinal canal stenosis, over a course of 42 months. In all cases, titanium cages and local bone graft were used for spondylodesis. The follow-up protocol of these 30 cases included standardised clinical and radiological evaluation at 3, 6, 12 and 42 months after surgery. Overall satisfactory results were achieved. With one exception, a stable result was achieved with restoration of the intervertebral space in the anterior column. After 42 months of follow-up in most cases, a radiologically visible loss of disc space height can be demonstrated. Clinically relevant migration of the cage in the dorsal direction was detected in one case. Based on our experience, posterior lumbar interbody fusion (PLIF) can be recommended for the treatment of monosegmental and bisegmental spinal stenosis, with or without segmental instability. Postoperative evaluation is mainly based on clinical parameters since the titanium implant affects the diagnostic

value of imaging studies and is responsible for artefacts. The results observed in our group of patients suggest that local autologous bone graft procured from the posterior elements after decompression is an adequate material for bone grafting in this procedure.

**Keywords :** spinal stenosis ; decompression ; posterior lumbar interbody fusion ; titanium cages.

---

■ Hans Trouillier, MD, Chief of Department.  
*Orthopaedic, Trauma and Spine Department, Franziskus Hospital Bielefeld, Germany.*

■ Hans Jürgen Refior, MD, Professor and Chairman emeritus.

■ Christof Birkenmaier, MD, Orthopaedic Surgeon.

■ Alexander Rauch, MD, Orthopaedic Surgeon.

■ Thomas Kauschke, Orthopaedic Surgeon.

*Department of Orthopaedic Surgery, Ludwig-Maximilian University Munich, Germany.*

■ Christoph Weiler, MD, Pathologist.

*Institute of Pathology, Ludwig-Maximilian University Munich, Germany.*

Correspondence : H. Trouillier, Orthopaedic Trauma and Spine Department, Franziskus Hospital, Academic Teaching Hospital of the University of Hannover, Kiskerstrasse 26, 33615 Bielefeld, Germany.

E-mail : dr.trouillier@ws-chirurgie.com.

© 2006, Acta Orthopædica Belgica.

## INTRODUCTION

Fusion operations in the lumbar spine have become well established over the last two decades. One of the most important indications is monosegmental degenerative discopathy with instability and spinal canal stenosis (1, 2, 3). Posterior lumbar interbody fusion (PLIF) can find an indication whenever a targeted decompression has weakened the dorsal osseous structures of the lumbar spine. Advantages are the purely dorsal approach, and the possibility of also reaching and stabilising the anterior spinal column, while avoiding the risks inherent to an anterior approach (1, 2, 3, 4).

In our study two contact fusion cages (Synthes®) were used for anterior column fusion, with the purpose to ensure anterior stability and to restore the height of the intervertebral space. Under axial compression, bony fusion can be expected to occur. After complete removal of the degenerated disk through the dorsal approach, the cages themselves as well as the ventral area and the space left between the cages are filled with cancellous bone, which is then in contact with the adjacent vertebral end plates. In addition, a posterior spondylodesis with the Universal Spine System I (USS I / Synthes®) and also posterolateral cancellous bone graft procured from the posterior elements after decompression is carried out. This technique of 360° fusion is meant to achieve primary stability and prevent segmental movement until bony fusion.

Among various cage designs, two have now been used extensively : one is the titanium implant used in this study ; the other is the so-called PEEK implant (PolyEtherEtherKetone) (20).

## PATIENTS AND METHODS

Thirty patients were treated with the PLIF technique through a dorsal approach at the Orthopaedic Department of the University of Munich Medical Center between May 1997 and May 2000. All 30 patients were examined clinically and radiologically in a thorough prospective follow-up after 3, 6, 12 and 42 months. This group consisted of 17 men and 13 women. The average age of the patients was 59 years (range, 33-76 years).

In 16 of the cases, the indication for PLIF was based on evidence of combined spinal stenosis and degenera-

tive discopathy, with radiologically documented instability. Instability was defined as spondylolisthesis of more than two millimeters demonstrated in extension/flexion films. Fourteen additional cases showed only degenerative discopathy and spinal stenosis. Fourteen of the 30 patients also had foraminal narrowing with spinal root entrapment in addition to the spinal stenosis, which required targeted foraminotomy.

Posterior lumbar interbody fusion was used in 21 cases in the L4/L5 segment, in 9 cases in the L5/S1 segment.

The VAS Back and Leg Pain Score, the Oswestry Disability Score, and the SF 36 – Questionnaire were used for documentation and evaluation of subjective and functional results. Score sheets were completed by all patients in cooperation with a physician preoperatively, as well as postoperatively at 3, 6, 12 and 42 months.

A special evaluation of the walking distance was included to document the functional results.

Complications were recorded in detail and are discussed below.

The radiological evaluation by an independent radiologist included the calculation of the preoperative and postoperative intervertebral space height. Standardized radiographs in two planes (AP and lateral) were used for measurement. If there was any question about the stability of the instrumentation or suspicion of pseudarthrosis, additional flexion – extension films and a high-resolution CT - scan were performed (15). The disc heights in the anterior and posterior part of the disc were measured in the lateral film and the two measurements were added for calculation. The height of the adjacent vertebrae was calculated in the same manner. The ratio of the added values calculated for disc height and vertebral height in percent allowed for objective documentation of postoperative changes in intervertebral space height, and also to determine whether restoration of the intervertebral space was achieved or whether loss of height had occurred in spite of the implant (fig 1).

## SURGICAL TECHNIQUE

Cage implantation was carried out in all cases according to a standardised operative procedure (1-5, 10, 12). After removal of the disc, the endplates of the vertebrae were denuded, without weakening the subchondral bone plates. The cage size was adapted to the standardized technique of contact fusion cages. The opposite side was distracted with the test cage of the same size.

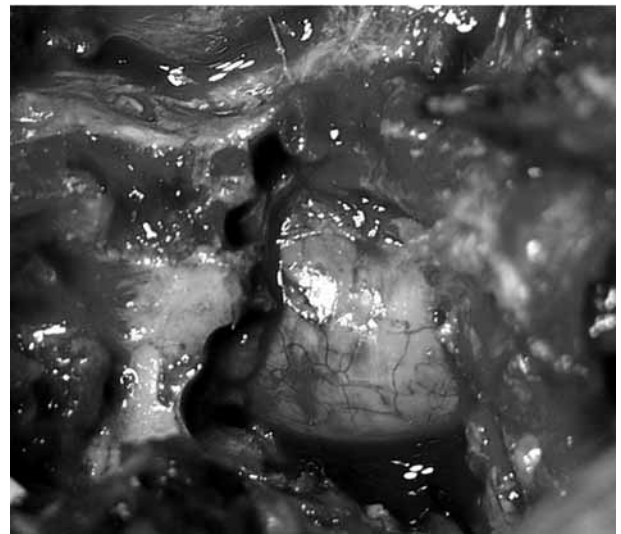
$$\frac{\text{Height of Intervertebral Disc Space}}{\text{Height of Vertebra}} \times 100\%$$

*Fig. 1.* — Formula used to calculate the ratio (%) of the disc height and vertebra height.

The extent of dorsal decompression was adapted to the clinical and anatomic necessities, but its extent varied little (fig 2). USS I (Synthes®) titanium pedicle screws were placed before decompression, to ensure their correct positioning. In all cases, local autogenous bone graft, preserved from segmental decompression, was used to perform the bony fusion (4, 17). The bone procured from the decompression was cleared of any soft tissue. Within the scope of the PLIF operation, cancellous bone from decompression was placed ventrally and between the cages after total discectomy. The dorsolateral spondylodesis was carried out using two rods in accordance with standard operative guidelines. After preparation of the remaining lamina parts and the transverse processes, autogenous corticocancellous bone graft was placed dorsolaterally.

## RESULTS

Assessment of the results was based on an evaluation made 3,6,12 and 42 months after surgery. Average and median values were calculated for the evaluation. There were no major differences between the individual results, which showed a normal distribution. Considering the small number of cases (n = 30), median values were listed, as they are less prone to distortions. The preoperative and 42-month values of the VAS (Visual Analogue Scale) Pain Score for the 30 patients showed a clear reduction in subjective pain perception. With regards to the VAS pain score, it should be pointed out that the score for leg pain fell from 62% preoperatively to 10%, 42 months after fusion and decompression. The back pain VAS score had a preoperative value of 80%, versus 30% after one year, and 45% after 3.5 years (fig 3).



*Fig. 2.* — Intraoperative view after decompression

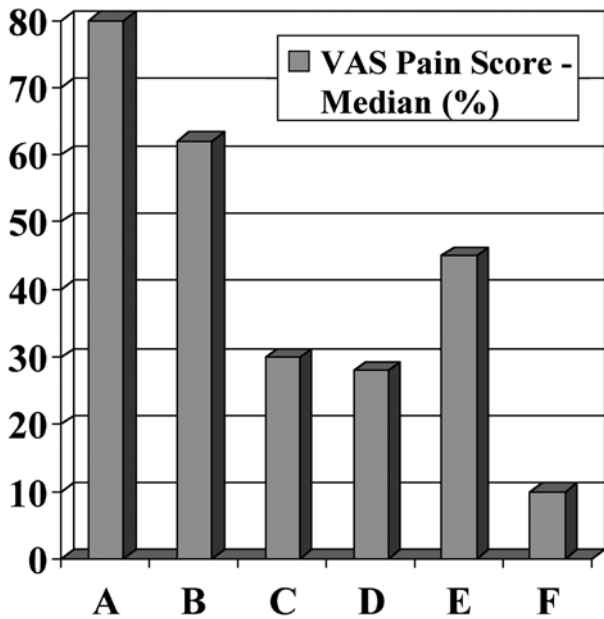
The median value of the Oswestry Disability Score for the whole study group was 58% preoperatively, 26% after one year, and 30% after 42 months (fig 4).

In the SF 36 Score, the preoperative percentage values for the individual parameters - Physical / Social / Role (physical) / Role (emotional) / Mental / Energy / Pain / Health perception - ranged between a minimum of 11% and a maximum of 56%. After one year, the values ranged between 40.6% and 65.3%. In the 42-month follow-up, the results were between 47.3% and 70% (fig 5).

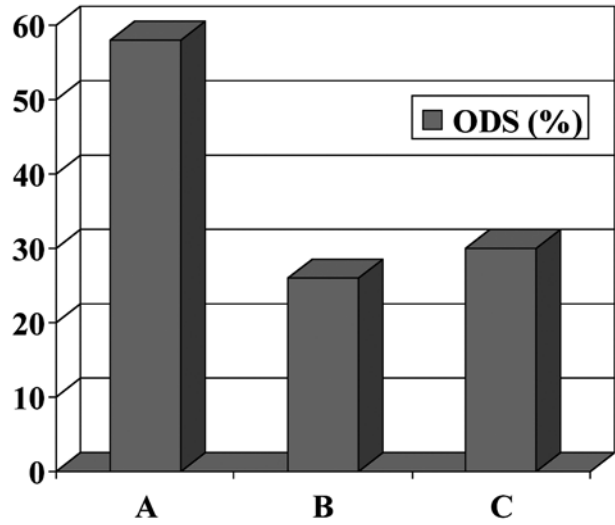
The walking distance was estimated from the above scores and direct questioning as an important additional criterion. After 42 months, 75% of the patients reported an improvement in walking distance of up to 500 meters. Fifty five percent of the patients reported an improvement in their walking distance of more than 1 kilometer.

The radiological restoration of the intervertebral space height was used as an criterion for a successful PLIF instrumentation. The relative values of disc space height immediately after operation and 3, 6, 12 and 42 months postoperatively are presented in figure 6 in an overview.

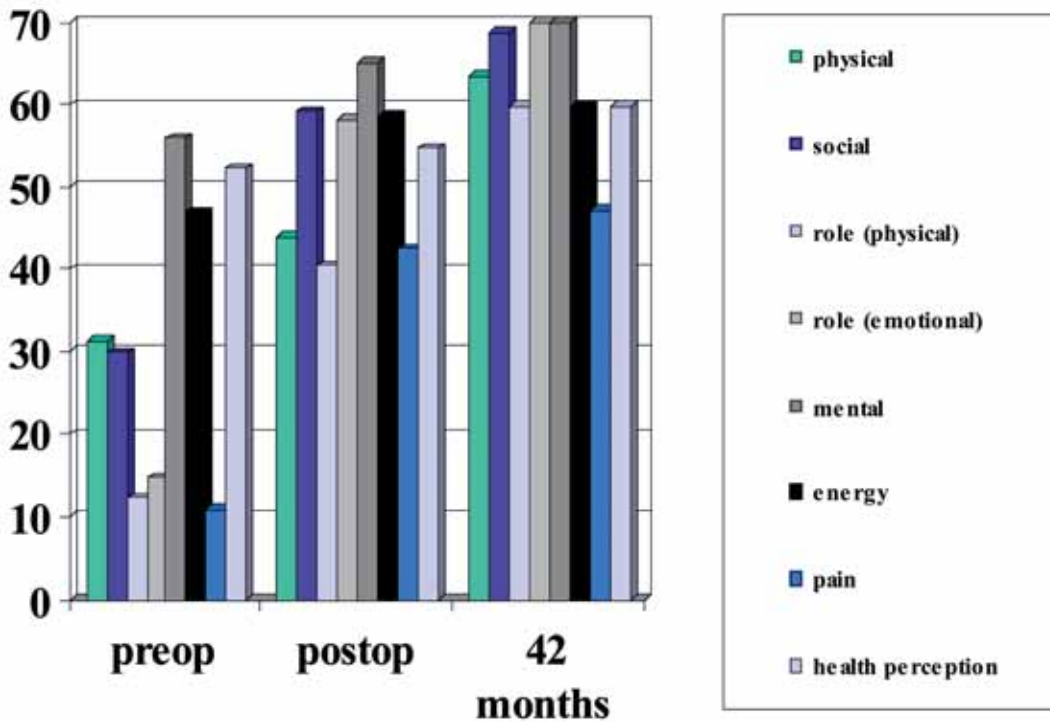
The intervertebral space height presented as a ratio as described above remained at 35% after the



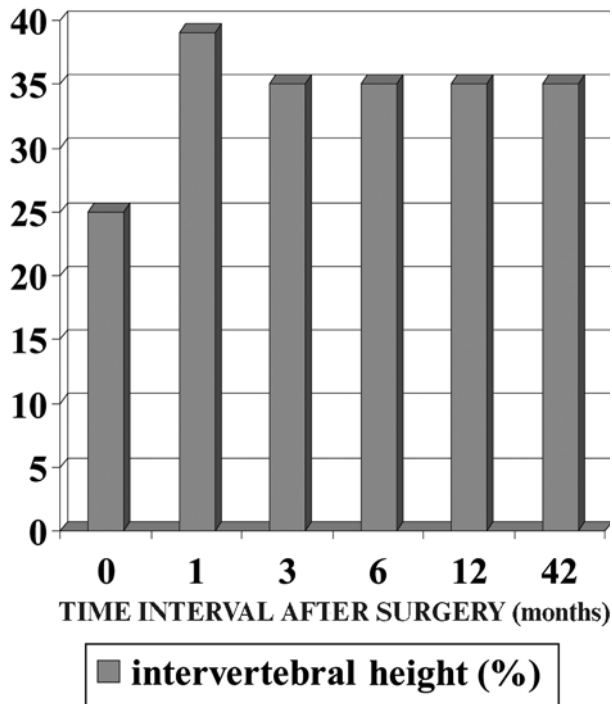
**Fig. 3.** — Results of VAS leg pain and back pain score (n = 30)  
 A = preop back pain ; B = preop leg pain ; C = postop back pain ; D = postop leg pain ; E = back pain 42 month ; F = leg pain 42 month.



**Fig. 4.** — Results and progress of Oswestry Disability Score (ODS) (n = 30).  
 A = ODS preop ; B = ODS postop ; C = ODS 42 month.



**Fig. 5.** — Results of SF 36 Score (n = 30)



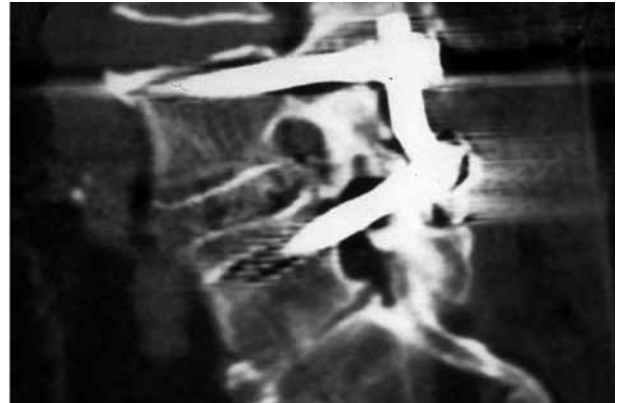
*Fig. 6.* — Radiological progress of the interbody space (n = 30)  
0 = preop ; 1 = postop ; 3 = 3 months postop ; 6 = 6 months postop ; 12 = 12 months postop ; 42 = 42 months postop.

3<sup>rd</sup> postoperative month, versus 39% immediately after operation and 25% preoperatively (fig 6).

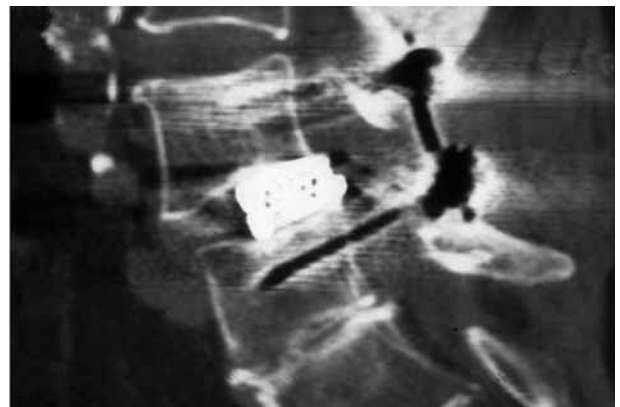
With regard to complications, the following specific problems were encountered : In one case, we observed pseudarthrosis formation, with screw breakage and dorsal migration of a cage, despite a seemingly solid ventral fusion with seemingly calcified bone formation in the intervertebral space as determined in plain films at the one-year follow-up (fig 7).

We subsequently revised this patient by means of a posterior-anterior procedure, which made it possible to examine histologically the retrieved tissue material (fig 8).

Histological examination of the material showed very slight appositional bone growth with primarily necrotic fibrous connective tissue, both in the tissue collected from the titanium cages and between them, on the ventral side, and on the lateral side of the cages (fig 9).



*Fig. 7.* — CT scan : slice between the cages, one year control

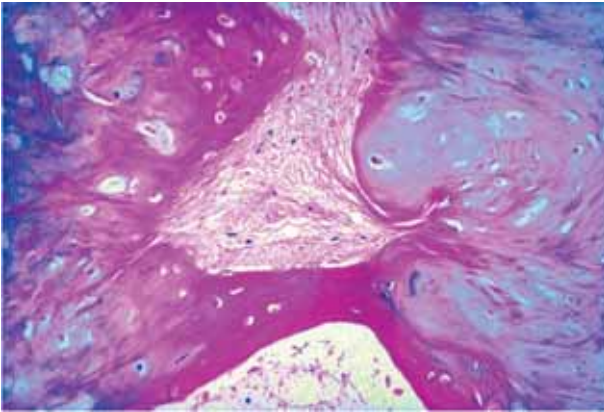


*Fig. 8.* — CT scan, 22<sup>nd</sup> month control

Radiologically, one patient demonstrated signs of loosening of the dorsal instrumentation. As he has remained symptom free until now, no re-operation has been planned as yet. Another patient with a misplaced screw is also asymptomatic. Still another patient showed signs of proximal adjacent segment instability following L4/5 instrumentation. He developed increasing complaints, but has not yet decided on an additional operation. One patient described unchanged persistent nerve root complaints in spite of targeted foraminotomy. Four patients reported sacroiliac joint pain at the 42-month follow-up. These complaints were listed under “back pain”.

General complications were one case of pulmonary embolism and one case of transient pleural effusion, but with an uneventful recovery.





**Fig. 9.** — Histological appearance of the pseudarthrosis tissue (haematoxylin – eosin staining).

## DISCUSSION

The most notable finding in this study was that leg pain was improved in all cases after targeted decompression. The back pain with all of its components, such as sacroiliac pain or complaints from the adjacent segment deteriorated however, after an initial improvement. From a preoperative pain score of 80% on VAS, the patients improved at the one-year follow-up to an estimated 30%. At 42 months, back pain had again increased to 45%. Thus, there was only a moderate improvement in back pain over the entire period of observation.

Both scores improved postoperatively, and the results of the Oswestry Disability Score and the SF-36 Score do not differ significantly. The tendency however reflects a clear overall subjective improvement. These results are in agreement with comparable studies (3, 5).

The use of autogenous bone preserved from spinal decompression achieved a satisfying number of stable fusions with a 5% failure rate (11, 16). The fusion rates reported in the literature range from 65% to 95% (6, 7, 8, 9, 13).

The intervertebral space height, calculated as described above, shows a systematic initial restoration despite the limited bearing surface of the cages. From a pre-operative value of 25%, it

increased to 39% immediately after operation, and remained stable at 35% until the 42<sup>nd</sup> month. An average postoperative loss of height of 4% can be calculated (range 6%-3%). In one case, cage migration in the dorsal direction was detected. Brantigan (2) described a comparable loss of height, which was on average 4 mm.

Most authors report early complications (6, 18, 19). The only revision necessary in this group, fused with local bone graft, took place after an evolution over 22 months. This would correspond to a 5% pseudarthrosis rate.

It must therefore be stated that the evaluation of the bony fusion is critical. McAfee, Boden and others discuss this problem in a similar manner (15). The decision whether the vertebrae fused or not can ultimately only depend on the clinical evolution and on an unchanged implant position, because of the well known artefacts in the radiographs and CT-films.

## SUMMARY

Posterior lumbar interbody fusion (PLIF) can be recommended in our opinion for monosegmental spinal stenosis, with or without segmental instability, provided that it can be corrected to Meyerding Degree I or better. In some situations, other diagnoses can also lend themselves to the PLIF technique, such as in patients who have already been operated upon through an anterior approach. Overall, however, we recommend that the use of this technique should be limited to the above-mentioned patient group. The inevitable weakening of the dorsal structures and the resulting iatrogenic reduction in stability of the spine is only justified when decompression is simultaneously carried out for spinal stenosis.

Local bone graft is sufficient to achieve a reliable fusion rate. The outcome of the PLIF procedure is at least comparable to that of combined ventral and dorsal procedures (14).

Overall, the results can be considered positive with regards to the subjective parameters. The postoperative evaluation of stable fusion with an indwelling titanium implant is mainly based on the clinical situation of the patient. It remains difficult

to establish whether fusion took place or not, based on radiological studies. Consequently, the correlation of persisting back pain with success or failure to achieve fusion, based on radiological imaging, must be discussed carefully.

## REFERENCES

1. **Brantigan JW, Steffee AD.** A carbon fiber implant to aid interbody lumbar fusion. Two-year clinical result in the first 26 patients. *Spine* 1993 ; 18 : 2106-2107.
2. **Brantigan JW.** Pseudarthrosis rate after allograft posterior lumbar interbody fusion with pedicle screw and plate fixation. *Spine* 1994 ; 19 : 1271-1279.
3. **Brantigan JW, Steffee AD, Lewis ML, Quinn LM, Persenaire JM.** Lumbar interbody fusion using the Brantigan I/F cage for posterior lumbar interbody fusion and the variable pedicle screw placement system : two-year results from a Food and Drug Administration investigational device exemption clinical trial. *Spine* 2000 ; 25 : 1437-1446.
4. **Csecsei GI, Klekner AP, Dobai J, Lajgut A, Sikula J.** Posterior interbody fusion using laminectomy bone and transpedicular screw fixation in the treatment of lumbar spondylolisthesis. *Surg Neurol* 2000 ; 53 : 2-6.
5. **Depraetere P, Jenny P.** Interbody cages in PLIF surgery : a multicentric report. *J Musculoskeletal Research* 1998 ; 2 : 9-14.
6. **Enker P, Steffee AD.** Interbody fusion and instrumentation. *Clin Orthop* 1994 ; 300 : 90-101.
7. **Eshkenazi AU, Dabby D, Tolessa E, Finkelstein JA.** Early retropulsion of titanium-threaded cages after posterior lumbar interbody fusion. *Spine* 2001 ; 26 : 1073-1075.
8. **Freeman BJC, Licina P, Mehidian SH.** Posterior lumbar interbody fusion combined with instrumented posterolateral fusion : 5-year results in 60 patients. *Eur Spine J* 2000 ; 9 : 42-46.
9. **Gill K, Blumenthal SL.** Posterior lumbar interbody fusion. A 2 year follow-up of 238 patients. *Acta Orthop Scand* 1993 ; 64 (Suppl 251) : 108-110.
10. **Jun BY.** Posterior lumbar interbody fusion with restoration of lamina and facet fusion. *Spine* 2000 ; 25 : 917-922.
11. **Kai Y, Oyama M, Morooka M.** Posterior lumbar interbody fusion using local facet joint autograft and pedicle screw fixation. *Spine* 2004 ; 29 : 41-46.
12. **Kuslich DS, Ulstrom C, Griffith SL, Ahern JW, Dowdle JD.** The Bagby and Kuslich method of lumbar interbody fusion. *Spine* 1998 ; 23 : 1267-1279.
13. **Lin PM.** Posterior lumbar interbody fusion technique : complications and pitfalls. *Clin Orthop* 1985 ; 193 : 90-102.
14. **Madan SS, Boeree NR.** Comparison of instrumented anterior interbody fusion with instrumented circumferential lumbar fusion. *Eur Spine J* 2003 ; 12 : 567-575.
15. **McAfee PC, Boden SD, Brantigan JW et al.** Symposium : a critical discrepancy - a criteria of successful arthrodesis following interbody spinal fusions. *Spine* 2001 ; 26 : 320-334.
16. **Miura Y, Imagama S, Yoda M, Mitsuguchi H, Kachi H.** Is local bone viable as a source of bone graft in posterior lumbar interbody fusion? *Spine* 2003 ; 28 : 2386-2389.
17. **Togawa D, Bauer TW, Brantigan JW, Lowery GL.** Bone graft incorporation in radiographically successful human intervertebral body fusion cages. *Spine* 2001 ; 26 : 2744-2750.
18. **Uzi EA, Dabby D, Tolessa E, Finkelstein JA.** Early retropulsion of titanium-threaded cages after posterior lumbar interbody fusion : a report of two cases. *Spine* 2001 ; 26 : 1073-1075.
19. **Wetzel FT, LaRocca H.** The failed posterior lumbar interbody fusion. *Spine* 1991 ; 16 : 839-845.
20. **Williams DF, McNamara A, Turner RM.** Potential of polyetheretherketone (PEEK) and carbon-fiber-reinforced PEEK in medical applications. *J Mater Sci Lett* 1987 ; 6 : 188-190.